



## Case Report: Suprachoroidal Catheterization “ab-interno” for Treatment of Open Angle Glaucoma: “BABLY TECHNIQUE”

Ahmed Said Ahmed Elbably<sup>1\*</sup>

<sup>1</sup>Department of Ophthalmology, Riyadh National Hospital, Riyadh, Saudi Arabia.

### Author's contribution

The sole author designed, analyzed and interpreted and prepared the manuscript.

### Article Information

DOI:10.9734/BJMMR/2015/14993

#### Editor(s):

(1) Ian Dooley, Limerick Regional Hospital, Republic of Ireland.

#### Reviewers:

(1) Anonymous, Korea.

(2) Anonymous, Italy.

(3) Elizabeth Awoyesuku, Department of Ophthalmology, University of Port Harcourt Teaching Hospital, Nigeria.

Complete Peer review History: <http://www.sciencedomain.org/review-history.php?iid=907&id=12&aid=7713>

### Case Study

Received 31<sup>st</sup> October 2014  
Accepted 3<sup>rd</sup> January 2015  
Published 9<sup>th</sup> January 2015

### ABSTRACT

A cataractous and open angle glaucomatous right eye of a 60 year old man was surgically treated in a different way. First, phacoemulsification with posterior chamber intraocular lens was done, then, under gonioscopy, I track, I science microcatheter was introduced in the suprachoroidal space and heavy viscoelastic was injected. Preoperatively, intra ocular pressure was 28 mmHg on three topical medications, Travatan, Cosopt and Alphagan. One month postoperatively, IOP was reduced to 16 mmHg without medications. Suprachoroidal catheterization is a safe, easy and effective technique in treatment of open angle glaucoma. Studies with long-term follow up are needed to assess efficacy and safety of the procedure. Suprachoroidal catheterization should be tried in different types of glaucoma.

*Keywords:* Suprachoroidal catheterization; open angle glaucoma; viscoelastic; cataract.

### 1. INTRODUCTION

Up to this moment, Canaloplasty was the only surgical technique that used microcatheter in

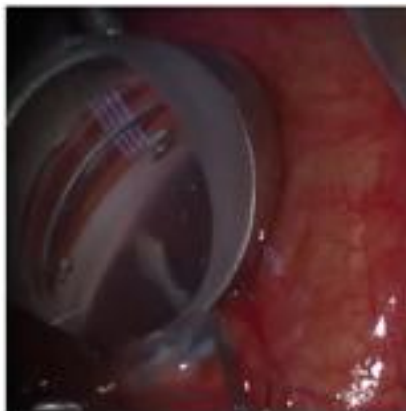
treatment of open angle glaucoma [1,2,3]. Nowadays, we can further use the microcatheter to enter the suprachoroidal space through the anterior chamber and inject viscoelastic to create

\*Corresponding author: Email: [drahmedelbably@gmail.com](mailto:drahmedelbably@gmail.com);

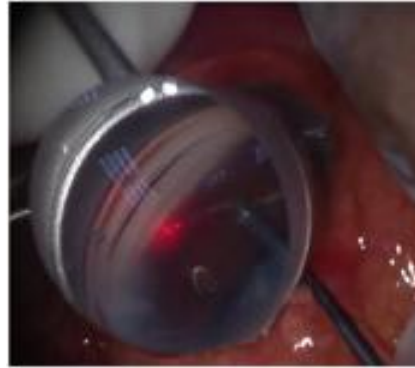
suprachoroidal pouch connected to the anterior chamber [4].

## 2. CASE REPORT

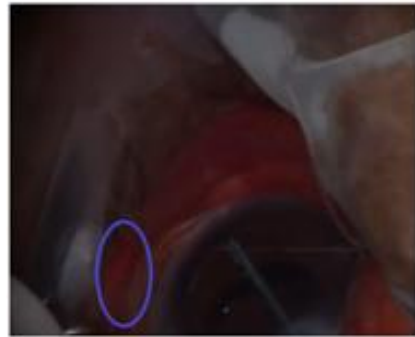
A 60-year-old gentleman presented to the clinic with defective vision in both eyes, uncorrected visual acuity of the right eye was hand movement with good projection and was counting fingers (1 meter) in the left eye. The patient's intraocular pressure was 28 mmHg in both eyes under three topical anti-glaucoma medications 10 years ago. The patient's last visual field assessment revealed double arcuate scotoma in addition to mature senile cataract in both eyes. Gonioscopy showed Shaffer grade 3 angle, while fundus could not be seen due to mature cataract. After obtaining ethics committee approval from Riyadh National Hospital, Riyadh, Saudi Arabia and signed informed consent from the patient, combined cataract and glaucoma surgery was performed. Routine phacoemulsification plus posterior chamber intra ocular lens was performed, Swan Jacob gonioscopes were used to visualize the angle, 1.1 stab knife created small incision between the scleral spur and the ciliary body (Fig. 1), the iTrack™250 micron diameter canaloplasty microcatheter with lumen (I science, United States) was introduced through the paracentesis to the anterior chamber then directed about 4mm into the suprachoroidal space using a forceps (Fig. 2). Small amount of Healon GV (3 full rounds of the injector screw) was injected suprachoroidally (Fig. 3). First day postoperatively, the intraocular pressure (IOP) was reduced to 12 mmHg. One month postoperatively, intraocular pressure was stable at 16 mmHg without medications, then 18 mmHg over the following 6 months.



**Fig. 1. Creating small incision between ciliary body and scleral spur**



**Fig. 2. Microcatheter is in the anterior chamber through paracentesis**



**Fig. 3. Microcatheter is in the suprachoroidal space with transillumination of the flickering tip**

## 3. DISCUSSION

The idea of approaching the suprachoroidal space ab-interno was used by The CyPass [5] Micro-Stent (a 6.35-mm long polyimide tube with an outer diameter of about 0.5 mm). The advantage of suprachoroidal catheterization over the cypass that it creates a localized suprachoroidal pouch which enhances the aqueous drainage [6,7]. The learning curve for that surgery is very short, so it would be easy for the non-glaucoma specialists to perform such surgery. Long-term follow up and ultrasound biomicroscopy are a must, to check if the pouch disappeared and if the intraocular pressure returned back to higher levels. Different amounts of viscoelastics have to be tried to reach the proper amount suitable for each glaucoma level, also different sites and numbers of viscoelastics injections have to be tested to meet different grades of glaucoma. Almost no bleeding in the angle had been noticed. While this case was

successful, a larger study is required to demonstrate safety and efficacy.

#### 4. CONCLUSION

Visco dilation of the suprachoroidal space ab-interno by canaloplasty microcatheter is novel, effective, safe and easy technique for the treatment of open angle glaucoma.

#### COMPETING INTERESTS

Author has declared that no competing interests exist.

#### REFERENCES

1. Ambresin A, Shaarawy T, Mermoud A. Deep sclerectomy with collagen implant in one eye compared with trabeculectomy in the other eye of the same patient. J Glaucoma. 2002;11:214-20.
2. Bull H, von Wolff K, Korber N, Tetz M. Three-year canaloplasty outcomes for the treatment of open-angle glaucoma: European study results. Graefes Arch Clin Exp Ophthalmol. 2011;249:1537-45.
3. Cameron BD, Field MW, Ball SF, Kearney JR. Circumferential viscodilation of Schlemm's canal with a flexible microcannula during non-penetrating glaucoma surgery. Digit J Ophthalmol. 2006;12:1-9.
4. Godfrey DG, Fellman RL, Neelakantan A. Canal surgery in adult glaucomas. Curr Opin Ophthalmol. 2009;20:116-21.
5. Hoh H, Grisanti S, Rau M, Ianchulev S. Two-year clinical experience with the CyPass Micro-Stent: Safety and Surgical Outcomes of a Novel Supraciliary Micro-Stent. Klin Monbl Augenheilkd. 2014;231:377-381.
6. Lewis RA, von Wolff K, Tetz M, Korber N, Kearney JR, Shingleton B, Samuelson TW. Canaloplasty: Circumferential viscodilation and tensioning of Schlemm's canal using a flexible microcatheter for the treatment of open-angle glaucoma in adults: Interim clinical study analysis. J Cataract Refract Surg. 2007;33:1217-26.
7. Stegmann R, Pienaar A, Miller D. Visco canalostomy for open-angle glaucoma in black African patients. J Cataract Refract Surg. 1999;25:316-22.

© 2015 Elbably; This is an Open Access article distributed under the terms of the Creative Commons Attribution License (<http://creativecommons.org/licenses/by/4.0>), which permits unrestricted use, distribution, and reproduction in any medium, provided the original work is properly cited.

Peer-review history:

The peer review history for this paper can be accessed here:  
<http://www.sciencedomain.org/review-history.php?iid=907&id=12&aid=7713>