



## **Evolution of Human Amniotic Membrane in Extraction Socket for Faster Wound Healing**

**S. P. Indra Kumar<sup>1\*</sup>, Afrose Fathima<sup>1</sup>, S. Deepika<sup>1</sup>, R. J. Aravind<sup>1</sup>, T. Kavin<sup>1</sup>,  
Gayathri Priyadharshini<sup>2</sup> and R. Narendar<sup>1</sup>**

<sup>1</sup>*Department of Oral and Maxillofacial Surgery, Vivekanandha Dental College for Women, Tiruchengode, India.*

<sup>2</sup>*Department of Periodontics, Vivekanandha Dental College for Women, Tiruchengode, India.*

### **Authors' contributions**

*This work was carried out in collaboration among all authors. Authors SPIK and GP designed the study and wrote the protocol. Authors AF and SD wrote the first draft of the manuscript and performed the statistical analysis. Author RJA managed the analyses of the study. Authors TK, GP and RN managed the literature searches. All authors read and approved the final manuscript.*

### **Article Information**

DOI: 10.9734/JAMMR/2020/v32i2430842

#### **Editor(s):**

(1) Dr. Sevgul Donmez, Mugla Sitki Kocman University, Turkey.

#### **Reviewers:**

(1) Piyaporn Kampeerapappun, Rajamangala University of Technology Krungthep, Thailand.

(2) Harun Achmad, Hasanuddin University, Indonesia.

Complete Peer review History: <http://www.sdiarticle4.com/review-history/65530>

**Original Research Article**

**Received 22 October 2020**

**Accepted 28 December 2020**

**Published 31 December 2020**

## **ABSTRACT**

**Background:** Preservation of extraction site with grafting shall always produce better healing results. Various materials have been used for this process and each material has its unique benefits and properties. Few such materials are Simvastatin, Bone ceramic, oxidized cellulose, bone allograft, etc. In this given study, 10 patients were placed Human amniotic membrane in their extracted socket and the results were reviewed after 7days, 14 days, 21 days, 1 month, 3 month and 6 month.

**Materials and Methods:** The samples are voluntary and those patients with no clinical abnormalities were included. Human amniotic membrane is received from Tata Memorial Hospital, Mumbai.

Ten patients who reported to Department of OMFS were selected for the augmentation procedure. After extraction, the Human amniotic membrane was placed in the extracted socket and secured with sutures. Post-operative visits scheduled after 7days, 14 days, 21 days, 1 month, 3 month and

6 month intervals for analyzing the healing property of amnion in the augmented extraction sockets.

**Results:** The results of this study have shown that Amniotic membrane has proven its effect, as it initiates faster wound healing of the extraction socket.

**Conclusion:** This article shall reveal the effectiveness of the Human amniotic membrane in rapid wound healing of the augmented extraction socket.

*Keywords: Human amniotic membrane; periodontal diseases; granulation tissue; mesenchymal cells.*

## 1. INTRODUCTION

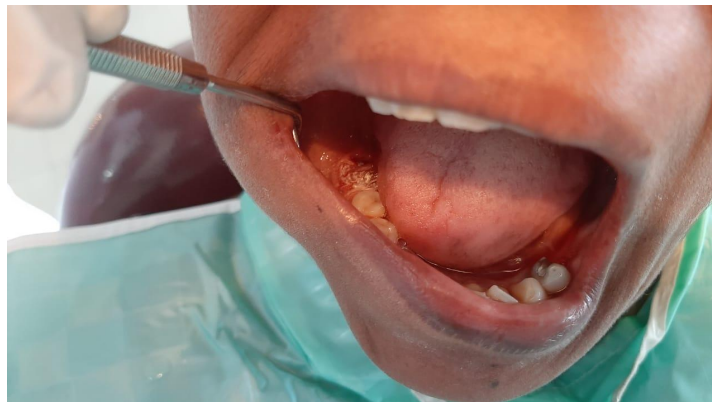Tooth extraction is the process of removal of tooth from the socket in the bone. Extraction shall also be referred as “tooth pulling” in common. Other names include, exodontia and exodontics. Those teeth which are not restorable due to dental caries, periodontal diseases, pericoronitis (in case of impacted tooth) and fracture shall be extracted. Therapeutic extractions are done when there is need for space in orthodontic management. Like other parts of our human body, the extracted socket also begins healing by the process of granulation. After extraction is done, there forms a clot followed by which granulation tissue formation occurs within the first 24 hours. From 7 to 14 days of healing process, the granulation tissue fills the socket with collagen rich blood vessels. With the granulation tissue the mesenchymal cells forms a network and initiates bone formation. By the end of 4<sup>th</sup> week, bone formation and maturation shall be under process. And it takes around 6 to 8 weeks for complete maturation of bone. Several faster wound healing materials have been used in extraction sockets such as local pressure applied with gauze, oxidized cellulose(gel form), socket graft [1], bone ceramic [2], simvastatin [3], fibrin sealant and amnion and chorion membrane [4-6] to

fasten the healing process. Each plays a different role and their rate of healing and outcome differs on formation of bone [7-9]. The placenta's inner layer is known as amniotic membrane and is adjacent to the amniotic fluid. The outer layer which is called chorionic membrane is next to the uterus and is considered as a maternal part of the placenta. Amniotic and chorionic membranes are strongly attached to each other. Its properties includes physical barrier, it reduces inflammation, reduces pain and scar, it fastens healing and its known for its antibacterial effect [10-15]. Human amniotic and chorionic membrane derived from placenta is rich in cytokines and growth factors which accelerates wound healing. Improper wound healing results in infection, pain, swelling, dry socket, etc. In order to avoid those complications, all the above mentioned properties are used for proper and early wound healing. This study primly focuses on the healing property of Amniotic membrane in intra- oral extracted tooth socket for accelerated wound healing.

## 2. MATERIALS AND METHODS

### 2.1 Study Design

This study is a pilot study conducted for a period of 6 months.



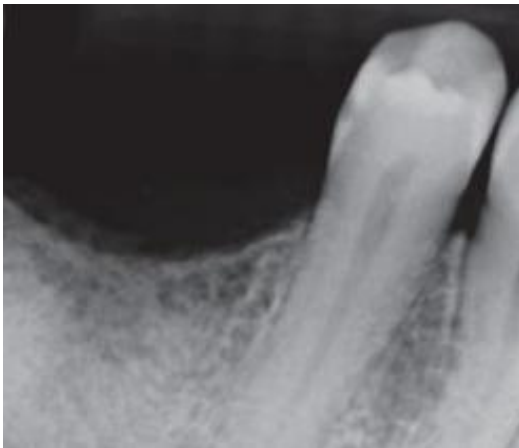
**Image 1. Human amniotic membrane placed in the extracted socket of Lower right first molar (46)**

## 2.2 Sample Selection

The study sample consists of 10 patients who came to Vivekanandha Dental College for women, Tiruchengode for dental treatment and referred to Department of Oral and Maxillofacial surgery for extraction. The samples includes voluntary and patients with no clinical abnormalities. Patients who are immune compromised, pregnant, non-cooperative, with history of allergy are excluded.

## 2.3 Protocol

- Step 1 : Under strict aseptic conditions, LA was administered.
- Step 2 : After anaesthetised, flap is elevated.
- Step 3 : Tooth is extracted and bleeding is arrested with gauze compression.
- Step 4 : Curettage is done in the extracted socket.
- Step 5 : Now amniotic membrane is placed in the extracted socket.
- Step 6 : Suturing is done over the membrane.
- Step 7 : Patient shall be recalled for review after 7 days, 14 days, 21 days, 1 month, 3 month and 6 month.



**Image 2. Radiograph of healed extraction socket**

## 3. RESULTS

In this study, the healing property of amniotic membrane have ominously contributed to the bone formation and healing in a shorter period. Based upon the current findings the placement of amniotic membrane in the extraction socket have shown satisfactory results. Further long term studies shall be held to further explore the

healing property of both amnion and chorion in extraction socket with other materials being used.

## 4. DISCUSSION

Extraction socket heals by secondary intention. After extraction of tooth, the socket is filled by blood and the clot formation takes place. From here both intrinsic and extrinsic pathway of clotting cascade begun. Initially within 24 to 48 hours of extraction, the process of organization occurs. In blood clot, neutrophils and macrophages are seen as a result of inflammatory response. The stages of synthesizing and proliferation takes place by the formation of osteogenic cells. By the end of 4<sup>th</sup> week, bone formation takes place. Human amniotic membrane is the innermost layer of placenta. It consists of a stromal matrix which is avascular and a thick basement membrane. It shall be used for wound healing as it hastens the process. The effectiveness of the dehydrated human amnion/chorion membrane (dHACM) has been shown in increasing the attached keratinized tissue over augmented extraction socket wounds and thus expanding the tissue [4]. Meanwhile the use of dHACM in a minimally invasive surgical approach reduces inflammation and pain and enhances open-socket grafting healing [5] Also the anti-inflammatory effects of amniotic membrane transplantation in ocular surface disorders [16] and the anti-angiogenic and anti-inflammatory proteins in human amniotic membrane has been proven effectively. This study attempts to assess the healing property of amniotic membrane in extraction socket for faster wound healing. Human amniotic membrane is obtained from Tata Memorial Hospital, Mumbai. Those membranes were placed in the extraction socket of a normal healthy patients who are not immuno compromised, pregnant, allergic and have no other medical histories. The results were found satisfactory on clinical assessment. Which proves that Human amniotic membrane does promotes faster wound healing.

## 5. CONCLUSION

In this article, the wound healing factors of the Human Amniotic-membrane has been pointedly proven as it have contributed to faster healing and following bone formation in a shorter period. Based on the current study, the placement of Amnion in extraction socket could show a promising and better results in intra-oral tissue

augmentation. Further long term studies will be held to confirm and compare these findings with other materials being used for fastening wound healing.

### CONSENT AND ETHICAL APPROVAL

As per university standard guideline, participant consent and ethical approval have been collected and preserved by the authors.

### COMPETING INTERESTS

Authors have declared that no competing interests exist.

### REFERENCES

1. Steiner, et al. The healing socket and socket regeneration. Compendium of Continuing Education in Dentistry. 1995;29(2):114-6, 118, 120-4.
2. Coster, et al. Healing of extraction sockets filled with Bone Ceramic® prior to implant placement: preliminary histological findings. Clinical Implant Dentistry and Related Research. 2011;13(1):34-45.
3. Saifi, et al. Healing of extraction socket following local application of simvastatin: A split mouth prospective study. J Oral Biol Craniofac Res. 2017;7(2):106-112.
4. Maksoud, et al. Tissue expansion of dental extraction sockets using dehydrated human amnion/chorion membrane: Case series. Clinical Advances in Periodontics. 2018;8:111-114.
5. Cullum, et al. Minimally invasive extraction site management with dehydrated amnion/chorion membrane (dHACM): Open-Socket Grafting. Compend Contin Educ Dent. 2019;40(3):178-183.
6. John V, et al. Socket preservation as a precursor of future implant placement: Review of the literature and case reports. Compend Contin Educ Dent. 2007;28(12): 646-53.
7. Bassir SH, et al. Systematic review and meta-analysis of hard tissue outcomes of alveolar ridge preservation. Int J Oral Maxillofac Implants. 2018;33(5):979-994.
8. Jambhekar S, et al. Clinical and histologic outcomes of socket grafting after flapless tooth extraction: A systematic review of randomized controlled clinical trials. J Prosthet Dent. 2015;113(5):371-82.
9. Tseng SC, et al. Modulation of acute inflammation and keratocyte death by suturing, blood and amniotic membrane in PRK. Invest Ophthalmol Vis Sci. 2000; 41(10):2906-14.
10. Talmi, et al. Anti-bacterial properties of human amniotic membrane. Placenta. 1991;12(3):285-8.
11. Mermet I, et al. Use of amniotic membrane transplantation in the treatment of venous leg ulcers. Wound Repair Regen. 2007; 15(4):459-64.
12. Abbas, et al. Assessment of amniotic and polyurethane membrane dressing in the treatment of burns. Burns: Journal of the International Society for Burn Injuries. 2010;36(5):703-10.
13. Jyoti, et al. Use of Chorionic membrane in periodontal therapy gives anti-inflammatory effect. Cell and Tissue Banking. 2013; 15(1).
14. Alexis, et al. Dehydrated amnion and chorion membrane in full thickness scalp defects. JAAD Case Rep. 2018;4(7):688-691.
15. Shimmura S, et al. Anti-inflammatory effects of amniotic membrane transplantation in ocular surface disorders. Cornea. 2001;20(4):408-413.
16. Hao Y, et al. Identification of antiangiogenic and anti-inflammatory proteins in human amniotic membrane. Cornea. 2000;19(3):348-52.

© 2020 Kumar et al.; This is an Open Access article distributed under the terms of the Creative Commons Attribution License (<http://creativecommons.org/licenses/by/4.0>), which permits unrestricted use, distribution, and reproduction in any medium, provided the original work is properly cited.

*Peer-review history:*  
*The peer review history for this paper can be accessed here:*  
<http://www.sdiarticle4.com/review-history/65530>