



## **Assessment of Proximal Radio-median Cubital/Radio-Cephalic Arterio-venous Fistula**

**Jawed Akther<sup>a#</sup>, Y. R. Lamture<sup>a#\*</sup>, Varsha P. Gajbhiye<sup>bt†</sup>, Ranjit Ambad<sup>ct†</sup>  
and Aditya V. Ghunage<sup>dt‡</sup>**

<sup>a</sup> Department of General Surgery, Jawaharlal Nehru Medical College, Datta Meghe University of Medical Sciences, Wardha, Maharashtra, India.

<sup>b</sup> Department of Pharmacology, Datta Meghe Medical College Nagpur, Datta Meghe University of Medical Sciences, Wardha, Maharashtra, India.

<sup>c</sup> Department of Biochemistry, Datta Meghe Medical College Nagpur, Datta Meghe University of Medical Sciences, Wardha, Maharashtra, India.

<sup>d</sup> Datta Meghe University of Medical Sciences, Wardha, Maharashtra, India.

### **Authors' contributions**

*This work was carried out in collaboration among all authors. All authors read and approved the final manuscript.*

### **Article Information**

DOI: 10.9734/JPRI/2021/v33i58A34158

### **Open Peer Review History:**

This journal follows the Advanced Open Peer Review policy. Identity of the Reviewers, Editor(s) and additional Reviewers, peer review comments, different versions of the manuscript, comments of the editors, etc are available here: <https://www.sdiarticle5.com/review-history/67573>

**Original Research Article**

**Received 10 October 2021  
Accepted 14 December 2021  
Published 15 December 2021**

### **ABSTRACT**

The present study aims to conducted the Assessment of Proximal radio-median cubital/radio-cephalic Arterio-venous Fistula. Arterio-venous Fistula is life line for long-term hemodialysis for end stage renal disease patients. The order of preference as per National Kidney Foundation/ Kidney Disease Out Come Quality Initiative (KDOQI) is distal Radio Cephalic fistula is considered as gold standard followed by elbow Brachio Cephalic Fistula, transposed Brachio-Basilic Fistula, forearm arterio-venous graft. This is a cross sectional-prospective interventional study, 05/2017 to 04/2019, JNMC, Wardha, MH, with sample size of 66 cases. Out of 66 cases 25 % patients had diabetes mellitus, 48% cases were suffering from chronic glomerulonephritis, 15 % cases were suffering hypertension, 6 % cases had COPD and another 6 % cases had some cardiovascular disease. About 54 % cases had previous access failure. In our study the mean flow volume for AV fistula in

<sup>#</sup>Professor,

<sup>†</sup>Associate Professor,

<sup>‡</sup>Resident of General Surgery,

proximal forearm was  $485 \pm 291$  ml/min on postoperative day 1,  $695 \pm 298$  on postoperative day 7 and  $755 \pm 347$  ml/min. Overall postoperative complications in 12% cases was reported in our case study though Yilmiz et al reported postoperative complications in 15% cases.

**Keywords:** Arterio-venous fistula; chronic glomerulonephritis; brachio-basilic fistula; cardiovascular disease.

## 1. INTRODUCTION

The native arteriovenous fistula (AVF) is recommended as the best vascular access for hemodialysis by the National Kidney Foundation / Kidney Dialysis Outcomes Quality Initiative (NFK/DOQI) clinical practice guideline. Patients with AVFs have the lowest risks of death, infections, and cardiovascular events and also the lowest costs to the health care system [1-6]. Arterio-venous Fistula is life line for long-term hemodialysis for end stage renal disease patients. The order of preference as per National Kidney Foundation/ Kidney Disease Out Come Quality Initiative (KDOQI) is distal Radio Cephalic fistula is considered as gold standard followed by elbow Brachio Cephalic Fistula, transposed Brachio-Basilic Fistula, forearm arterio-venous graft. There appears increase in failure rates of distal arterio venous fistulas created over wrists in recent years as a result of poor vein quality in distal veins and arteries combined with history of intravenous catheterizations, diabetes mellitus, peripheral vascular disease (PVD) and old age [7].

Because of 20-50% chance for non-maturation (distal Radio Cephalic » Brachio cephalic fistula) & 10-20% chance for Dialysis Access Steal Syndrome of Brachio Cephalic Fistula, Bonforte et.al (2004) demonstrated Arterio-Venous Fistula of proximal Radial artery to nearest vein (cephalic / median anti-brachial / perforating vein) [7].

Arterio-Venous Fistulas using proximal Radio Cephalic have excellent patency rate, allowing multiple access sites in proximal forearm [7] The latest KDOQI guidelines recommend newly created fistulas to be physically examined within 4–6 weeks and additional imaging studies if the fistula is not adequately matured by the sixth week [8]. Arterio-Venous Fistula maturation becomes apparent as early as 2–4-wks after creation. Arterio-Venous Fistula is considered sono-graphically matured if its Vein internal diameter  $\geq 4$  mm and flow volume (FV)  $\geq 500$  ml/min. (UAB) [9] Brachial artery flow volume predicts arterio-venous fistula maturation for both forearm & arm [10].

Low FV and small Vein Internal Diameter at 2-wks are predictive of arterio-venous fistulas that may not develop optimally at 6-wks. Michelle L. Robbin et al. [9] in his study with 602 patients in 2016 suggested that Early (USD) identification of causal lesions and problem-directed interventions shortens the time of fistula maturation & minimizes complications of central venous catheter use [8].

Assessing outcomes (maturation & Post-operative complications) of proximal Radial-Median Cubital/ radio cephalic(PR-MC/RC) arterio-venous fistula up to 2-wks and collecting data from dialysis unit about fistula functioning status for 1 year. To assess anatomical maturation at post-operative day one, day seven and 14 th post-operative day ( $D_1$ ,  $D_7$ , &  $D_{14}$ ). To assess postoperative complications  $\leq 2$ -weeks of surgery. To collect information of fistula functioning status for 1 year.

## 2. MATERIALS AND METHODS

This is a cross sectional-prospective interventional study, 05/2017 to 04/2019, JNMC, Wardha, MH.

With sample size of 66 cases

- Study design -Cross sectional prospective interventional
- Institute- AVBRH Sawangi Meghe, Wardha
- Sample size – 66 cases
- Statistical analysis done by SPSS (Statistical Package for the Social Sciences) software , version 27.0

### 2.1 Inclusion Criteria

1. Artery internal diameter  $\geq 2$  mm
2. Internal diameter  $\geq 2.5$  mm (milli meter)
3. Non-dominant hand
4. Failed distal radio cubital arterio-venous fistula
5. Absence of stenosis or thrombosis in the draining vein

## 2.2 Exclusion Criteria

1. Blood flow less than 50ml/min
2. Vascular access less than 15 days on the target arm
3. Hypotensive  $\leq$  110/70 mmhg
4. Advanced heart failure
5. do not sign the informed consent

## 2.3 Details of Procedure

Patient profile including age, sex, BMI & comorbidities like DM, HTN, hyperlipidemia, CD, PVD & COPD. "Fast, 5-min Dialysis Duplex Scan," [10] - (Pre-op. & post-op.).

A lazy 'S' shaped skin incision centering in line with the brachial artery pulsation till 4cm below the elbow crease ↓LA. Identification, dissection, & mobilization of A & V. After applying clamps (6 – 8 mm) arteriotomy and venotomy were made.

Vein was distended & flushed with heparinized saline by 6 Fr feeding tube in side vein. The M-CV / CV was anastomosed to the pRA in end to side fashion 2 cm below bifurcation of BA by proline 6-0/7-0 suture in a simple continuous manner. Wound was closed in layers with drain, if oozing present.

PSV, EDV, ID, calcification, compressibility, depth & continuity of vessels.  $FV (ml/min) = TAV \times A^2$

$$[TAV \approx EDV + 1/3 (PSV-EDV), A = \pi \times r^2]$$

[TAV- Timed Average Velocity, EDV- End diastolic Velocity, PSV- Peak Systolic velocity, A- Area, r- radius]

Statistical analysis done by SPSS (Statistical Package for the Social Sciences) software  
M-C V / CV- Median Cubital vein/ Cephalic Vein

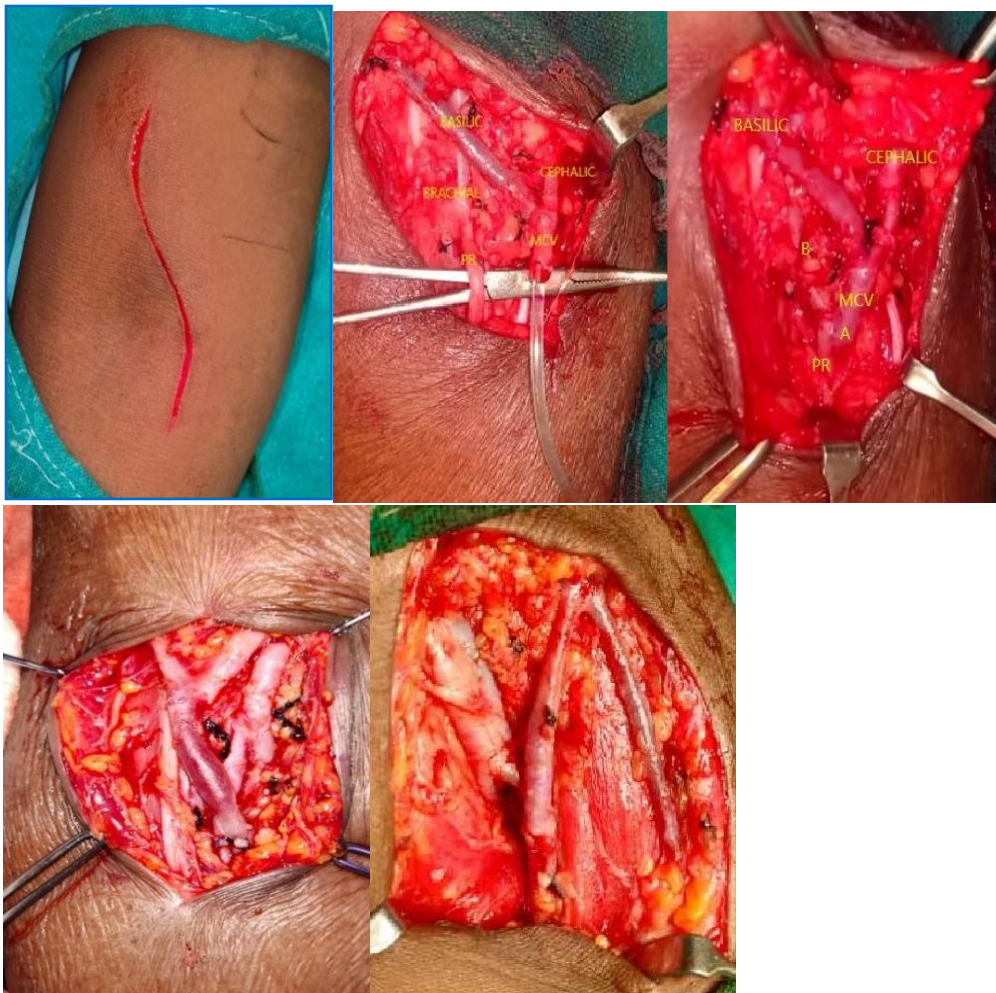


Fig. 1. Morphological view of the cases

### 2.4 Study Definitions as Per North American Vascular Access Consortium (NAVAC) Given Below

- D<sub>1</sub> → Immediately after surgery up to 2 days.
- Technical success → presence of a thrill or a bruit immediately and / 24 h postoperatively.
- Primary failure → Thrombosis or inability to cannulate AV fistula within 3 months of creation
- Immediate failure → failure ≤ 72 hrs.
- **Early dialysis suitable failure** → Arterio-venous fistula for which, despite the interventions (radiological/surgical), it is not possible to use successfully for HD by 3rd month following creation.

- Primary patency → time from arterio-venous fistula maturation to the first intervention.

### 3. RESULTS

Total 66 cases were studied between 05/2017 to 04/2019. Out of 66 cases 6 cases failed at 3 months (primary failure). Remaining 60 cases were mature at 1 year.

In present study we had male to female ratio of 0.94 with mean age as 43 years. Out of 66 cases 25 % patients had diabetes mellitus, 48% cases were suffering from chronic glomerulonephritis, 15 % cases were suffering hypertension, 6 % cases had COPD and another 6 % cases had some cardiovascular disease. About 54 % cases had previous access failure.

**Table 1. Comparison of patient’s characteristics with other authors**

Characteristics of patients	Present study	Gruidah A. <sup>5</sup> et al 2019	Yilmiz S. <sup>6</sup> et al 2015	Kumar A. <sup>7</sup> et al 2007	Ehsan O. <sup>8</sup> et al 2005
M/F	32 / 34	9 / 21	31 / 35	256 / 64	13 / 19
Age (Years)	43 (25-72)	52.7 (28-76)	49.6 (22-77)	32 (14-64)	61 (34-80)
DM	25%	80%	40.9%	25%	96.9%
CGN	48%	-	-	-	-
HTN	15%	30%	57.5%	-	-
CVS disease	6%	22.4%	-	-	-
COPD	6%	-	0.9%	-	-
Previous Access failure	54%	20%	62.1%	85%	0%

**Table 2. Comparison of Operative and post-operative patient’s variables with other authors**

Operative & Post-operative variables	Present study	Gruidah A. et al <sup>5</sup> 2019	Yilmiz S et al <sup>6</sup> 2015	Wu C. et al <sup>1</sup> 2015	Kumar A. et al <sup>7</sup> 2007	Ehsan O et al <sup>8</sup> 2005
Operative time (min)	85±10	-	-	-	55±7.15	45-60
Left / Right	10 / 1	-	41 / 25	-	7/1	32 / 0
Technical success	100 %	100 %	-	-	100 %	-
Palpable dR pulse	100 %	-	100 %	-	100 %	-
Primary failure	1.5%	0 %	4 %	1.2-33 %	4 %	9%
Preferred access for cannulation	Cephalic 88%	Cephalic 100%	Cephalic 100%	-	Cephalic 70%	-

**Table 3. Vein internal diameter (VID)**

Draining Vein ID (mm) (Cephalic)	Present Study	Toregeani et al <sup>10</sup> 2008	Han A. et al <sup>2</sup> 2016	Toregeani et al <sup>10</sup> 2008
		Prox. forearm	Dis. forearm	Mixed
Pre Operative	3.47 ± 1.41	3.24 ± 1.43	-	3.71 ± 1.37
Post. Operative	D <sub>7</sub>	5.28 ± 1.39	4.73 ± 0.87	-
	D <sub>14</sub>	5.54 ± 1.68	4.86 ± 1.05	4.41 ± 1.07
				6.02 ± 1.38

**Table 4. Comparative findings with other authors of the Flow volume for AVF**

Post Oper. Period	Flow volume (mL / min) for AVF						
	Proximal Forearm Present Study	Distal Forearm		Distal Forearm + Up. Arm		Up. Arm	
		Zhu et al <sup>9</sup> 2016	Toregeani et al <sup>10</sup> 2008	Asif A. et al <sup>11</sup> 2006	Yerdel M A. et al <sup>12</sup> 1997		Han A. et al <sup>2</sup> 2016
D <sub>1</sub>	485 ± 291	364 ± 151	-	-	539 ± 276	-	-
D <sub>7</sub>	695 ± 298	-	493.6 ± 257.5	-	848 ± 565	-	976.3 ± 332.9
D <sub>14</sub>	755 ± 347	634 ± 239	521.3 ± 264.4	692.3 ± 351.2	-	507.4 ± 194.6	1137.7 ± 430.0

**Table 5. Patency of arterio venous fistula**

Patency of Arterio-Venous Fistula	Present study	Gruidah A <sup>5</sup> et al 2019	Yilmiz S <sup>6</sup> et al 2015	Wu C et <sup>1</sup> al 2015	Kumar <sup>7</sup> et al 2007	Ehsan O <sup>8</sup> et al 2005
Primary	D <sub>14</sub>	98.5%	-	97.0%	-	-
	3 mo	94.0%	-	-	-	95%
	6 mo	91.0%	-	84.8%	-	-
	1 yr	91.0%	63.3%	-	85.7%	92.5%
						90.6%

**Table 6. Comparative Post-operative complications with other authors**

Post operative Complications	Present study	Gruidah A <sup>5</sup> et al 2019	Yilmiz S. <sup>6</sup> et al 2015	Kumar A. <sup>7</sup> et al 2007	Ehsan O. <sup>8</sup> et al 2005
Acute thrombosis	0%	13.3%	6%	-	6.2%
Bleeding	0%	-	-	0%	-
Hematoma	4.5%	-	1.5%	-	-
Arm oedema	7.5%	6.7%	3%	-	-
Wound infection	0%	-	0%	6.3%	3.1%
Wound dehiscence	0%	-	0%	2.2%	-
Pseudoaneurysm	3%	6.7%	0%	0.3%	-
Thrombophlebitis	0%	-	1.5%	5.6%	-
DIALYSIS ACCESS STEAL SYNDROME	0%	0%	0.5%	0%	0%
Overall	12%	-	15%	-	-

In present study mean operative time was observed as 85 min  $\pm$ 10 min, out of all the cases operated 10 cases were operated on non-dominant upper limb i.e., left upper limb. Technical success was 100 percent. Distal radial pulse was palpable in 100 % cases. There were 1.5 % patients who had primary failure. The preferred access for cannulation was cephalic in about 88% cases.

In our study mean venous internal diameter preoperatively was 3.47  $\pm$  1.41. postoperatively on day 7 and day 14 it was about 5.28  $\pm$  1.39 and 5.54  $\pm$  1.68 respectively.

In our study the mean flow volume for AV fistula in proximal forearm was 485 $\pm$  291 ml/min on postoperative day 1, 695  $\pm$  298 on postoperative day 7 and 755 $\pm$  347 ml/min.

In present study the primary patency at post-operative day 14 was 98.5 %, at 3 months 94 %, at 6 months it was 91 % and at 1 year it was 91%.

In this study none of the patients developed acute thrombosis, bleeding, wound infection, wound dehiscence, thrombophlebitis or Dialysis Associated Steal Syndrome though there were 4.5% cases who developed hematoma. 7.5 % cases developed arm edema and 3 % cases developed pseudo-aneurysm.

#### 4. DISCUSSION

In present study we had male to female ratio of 0.94 with mean age as 43 years. Out of 66 cases 25 % patients had diabetes mellitus, 48% cases were suffering from chronic glomerulonephritis, 15 % cases were suffering hypertension, 6 % cases had COPD and another 6 % cases had some cardiovascular disease. About 54 % cases had previous access failure. Gruidah et al did a case study on 30 patients in 2019 in which 9 patients were males and 21 were females, the mean age was 52.7 years. [11] about 80 percent cases had history of DM, 30 percent cases had hypertension, 22.4 percent cases had cardiovascular disease and 20 percent cases had history of previous access failure. Yilmiz et al studied 66 cases in 2015 out of which there were 31 males and 35 females with mean age of 49.6 years. In his study about 57.5 % cases had history of hypertension, 0.9% cases had history of COPD and 62.1 % had history of previous access failure. Kumar et al did case series on 320 patients out of which 256 were males and 64

were females with mean age of 32 years, about 25 % patients had history of diabetes mellitus and 85 % cases had history of primary access failure. Ehsan et al studied 32 cases in 2005 of which 13 were males and 19 were females with mean age of 61 years, 96.9% cases had history of diabetes mellitus (Table 1) [12].

In present study mean operative time was observed as 85 min  $\pm$ 10 min, out of all the cases operated 10 cases were operated on non-dominant upper limb i.e., left upper limb. Technical success was 100 percent. Distal radial pulse was palpable in 100 % cases. There were 1.5 % patients who had primary failure. The preferred access for cannulation was cephalic in about 88% cases. Gruidah et al. [11] reported 100 % technical success with cephalic route as 100 % preferred access for cannulation. Yilmiz et al. [12] performed 66 AV fistulas of which 41 were performed on non-dominant left upper limb and 25 on dominant limb i.e., right upper limb, distal radial pulse (dR) was palpable in 100 % cases with primary failure rate of 4 % and cephalic route as preferred access for cannulation in 100 % cases. The mean operative time for Kumar et al. [1] was 55  $\pm$ 7.15 min, with technical success rate and palpable distal radial pulse in 100% cases, primary failure was noted among 4 % cases. Ehsan et al reported minimum operative time average 45 to 60 min, he performed all the surgeries on left upper limb, also he noted primary failure rate in 9 % cases (see Table 2) [2].

In our study mean venous internal diameter preoperatively was 3.47  $\pm$  1.41. postoperatively on day 7 and day 14 it was about 5.28  $\pm$  1.39 and 5.54  $\pm$  1.68 respectively.

Toregeani et al. [2] reported 3.24 $\pm$ 1.43 mm as mean draining vein internal diameter (VID) in distal forearm pre operatively whereas at post-operative day 7 there was increase in VID mean VID was 4.73 $\pm$  0.87 mm and on post-operative day 14 it was 4.86  $\pm$  1.05 mm. Han et al in 2016 reported mean VID on post-operative day 14 as 4.41 $\pm$ 1.07 mm. Toregeani et al reported 3.71 $\pm$ 1.37 mm as mean VID pre operatively in upper arm which was increased to 5.84 $\pm$ 1.23mm on post-operative day 7 and 6.02 $\pm$ 1.38mm on post-operative day 14. the above findings were consistent with our study(see Table 3).

In our study the mean flow volume for AV fistula in proximal forearm was 485 $\pm$  291 ml/min on

postoperative day 1,  $695 \pm 298$  on postoperative day 7 and  $755 \pm 347$  ml/min. Zhu et al. in 2016 [1] evaluated mean flow volume of  $364 \pm 151$  ml/min on post op day 1 where as it was found to be increased to  $634 \pm 239$  ml/min on post op day 14. Toregeani et al. [2] reported mean flow volume of  $493.6 \pm 257.5$  mm on post op day 7 and  $521.3 \pm 264.4$  mm on post op day 14. Both above values were calculated on distal forearm, whereas Asif A et al in 2006 reported  $692.3 \pm 351$  ml/min on post op day 14, Yerdel et al in 1997 reported flow volume of  $539 \pm 276$  ml/min on post op day 1 and  $848 \pm 565$  on post op day 7, Han et al reported mean flow volume of  $507.4 \pm 194.6$  on post op day 14. Both above studies were done on distal forearm with upper arm. Toregeani et al reported flow volume of  $976.3 \pm 332.9$  ml/min whereas on post op day 14 it was  $1137.7 \pm 430$  ml/min (see Table 4) [2].

In present study the primary patency at post-operative day 14 was 98.5 %, at 3 months 94 %, at 6 months it was 91 % and at 1 year it was 91%. Gruidah et al. [11] reported primary patency of arterio venous fistula was 63.3 % after 1 year. Yilmiz et al. [12] reported primary patency of 97.7 % on post op day 14 and 84.8 % at 6 months. Wu C et al reported primary patency of 85.7% at 1 year, whereas Kumar et al. [1] reported 95 % patency at 3 months and 92.5% at 1 year. Ehsan et al reported 90.6 % patency at 1 years (see Table 5).

In this study none of the patients developed acute thrombosis, bleeding, wound infection, wound dehiscence, thrombophlebitis or Dialysis Associated Steal Syndrome though there were 4.5% cases who developed hematoma. 7.5 % cases developed arm edema and 3 % cases developed pseudo- aneurysm. Gruidah et al. [11] reported 13.3% cases had developed acute thrombosis of cephalic vein. Ehsan et al. reported 6.2% cases developing cephalic vein thrombosis. In our study none of cases developed the same. Yilmiz [12] reported 1.5% cases developed hematoma but, in our study, higher rate of 4.5% was noted. Arm edema was developed in 6.7 % cases reported by Gruidah et al. [11] whereas 3% was noted in study done by Yilmiz et al. [12] Kumar et al. [1] and Ehsan et al. [2] noted wound infection in 6.3% and 3.1 % cases respectively fortunately none of the cases developed wound infection in our case study. Kumar et al noted wound dehiscence in 2.2% cases, in our study none developed wound dehiscence. Pseudo- aneurysm was seen in 6.7

% cases in study done by Gruidah et al. [11] and 0.3 % in study done by Kumar et al, in our case study 3% cases developed pseudo-aneurysm. Thrombophlebitis was seen in 1.5% and 5.6 % in case studies done by Yilmiz et al. [12] and Kumar et al. [1] respectively. Dialysis access steal syndrome was reported in 0.5 % cases in study done by Yilmiz et al. [12] but none were reported in our case series. Overall postoperative complications in 12% cases was reported in our case study though Yilmiz et al. [12] reported postoperative complications in 15% cases (see Table 6).

- Intra-operative options for another artery & vein.
- Number of surgical failures was low comparable to elbow fistula.
- Timely increment of FV & Vein Internal Diameter of proximal forearm fistula were better than distal forearm.

## 5. CONCLUSIONS

Proximal forearm arterio-venous fistula should be recommended as 2nd option after failed / when not fit for distal forearm arterio-venous fistula. We believe that a proximal radiocephalic approach should be used before creating a brachiocephalic fistula in patients with prior forearm arterio-venous (AV) fistula dysfunction or insufficient wrist vessels to avoid dialysis-associated steal syndrome.

## CONSENT AND ETHICAL APPROVAL

Informed consent was taken patients and take institutional ethical committee approval.

## COMPETING INTERESTS

Authors have declared that no competing interests exist.

## REFERENCES

1. Kumar A, Jha MS, Singhla M. Radio-median cubital / radiocephalic arteriovenous fistula at elbow to prevent vascular steal syndrome associated with brachiocephalic fistula: Review of 320 cases. Indian J Urol. 2007;23(3):261–264.
2. Ehsan O, Bhattacharya D, Darwish A, Al-khaffaf H. Extension technique: A modified technique for brachio-cephalic fistula to

- prevent dialysis access-associated steal syndrome. *Eur J Vasc Endovasc Surg.* 2005;29.
3. Zhu YL, Ding H, Fan P, Gu Q, Teng J, Wang WP. Is brachial artery blood flow measured by sonography during early postoperative periods predictive of arteriovenous fistula failure in hemodialysis patients? *J Ultrasound Med.* 2016;35:1985–1992.
  4. Toregeani J F, Kimura C J, Antonio S. et al. Evaluation of hemodialysis arteriovenous fistula maturation by color-flow Doppler ultrasound. *J. vasc.bras.* 2008;7(3).
  5. Asif A, Roy-Chaudhury P, Beathard GA: Early arteriovenous fistula failure: A logical proposal for when and how to intervene. *Clin J Am Soc Nephrol.* 2006;1:332–339.
  6. Yerdel MA, Kesenci M, Yazicioglu KM, Doseyen Z, Turkcapar AG, Anadol E: Effect of haemodynamic variables on surgically created arteriovenous fistula flow. *Nephrol Dial Transplant.* 1997;12: 1684–1688.
  7. Wu C C, Jiang H, Cheng J. The outcome of the proximal radial artery arteriovenous fistula. *J Vasc Surg.* 2015; 61:802-8.
  8. Han A, Min S K, Kim M, Joo K W, Kim J, Ha J, Lee J, and Min S. A Prospective, randomized trial of routine duplex ultrasound surveillance on arteriovenous fistula maturation. *Clin J Am Soc Nephrol.* 2016;11:1817–1824.
  9. Robbin ML, Greene T, Cheung AK. Arteriovenous Fistula Development in the First 6 Weeks after Creation. *Radiology.* 2016;279(2):620–629.
  10. Ko SH, Bandyk DF, Hodgkiss-Harlow KD. Estimation of brachial artery volume flow by duplex ultrasound imaging predicts dialysis access maturation. *J Vasc Surg.* 2015;61:1521-8.
  11. Hesham S. Gruidah A, Mahmoud S. Abd El-Haleim, Mohamed A. Haridy. Evaluation of the proximal radio cephalic arteriovenous fistulafor hemodialysis. *Menoufia Medical Journal.* 2019;32:534–538.
  12. Yilmaz S, Aksoy E, Gunaydin S. Radio-medyan cubital arteriovenous creation for hemodialysis access. *Turkish Journal of Thoracic and Cardiovascular Surgery;* 2015.

© 2021 Akther et al.; This is an Open Access article distributed under the terms of the Creative Commons Attribution License (<http://creativecommons.org/licenses/by/4.0>), which permits unrestricted use, distribution, and reproduction in any medium, provided the original work is properly cited.

*Peer-review history:*

*The peer review history for this paper can be accessed here:*  
<https://www.sdiarticle5.com/review-history/67573>