



## **Lymphocystic Disease in Wild Croaker (*Micropogonias furnieri*) and Flounder (*Paralichthys orbignyanus*)**

**V. F. Pedrosa<sup>1\*</sup>, M. C. Klosterhoff<sup>2</sup>, A. F. F. de Medeiros<sup>1</sup>, C. A. Paz-Villarraga<sup>3</sup>  
and L. A. Romano<sup>1</sup>**

<sup>1</sup>Laboratory of Immunology and Pathology of Aquatic Organisms, Institute of Oceanography,  
Federal, University of Rio Grande, Rio Grande, Brazil.

<sup>2</sup>Federal University of Pampa, Upper Course of Technology in Aquaculture,  
Campus Uruguaiana, RS, Brazil.

<sup>3</sup>Laboratory of Organic Microcontaminants and Aquatic Ecotoxicology, Institute of Oceanography,  
Federal University of Rio Grande, RS, Brazil.

### **Authors' contributions**

*This work was carried out in collaboration among all authors. Authors VFP and LAR made the diagnosis. Author MCK managed the writing and research of literature. Author CAPV was responsible for forwarding the exemplary of *Micropogonias furnieri*. Author AFFM managed the sample processing for histopathological analysis. All authors read and approved the final manuscript.*

### **Article Information**

DOI: 10.9734/AJRIZ/2020/v3i330094

#### Editor(s):

(1) Dr. Jean Beguinot, University of Burgundy, France.

(2) Dr. Golam Mustafa, Bangladesh.

#### Reviewers:

(1) Homagni Sikha Roy, South West Medical University, China.

(2) Kanchana Subbiah, India.

(3) Vidhya Manohar, Norwich University NHS Foundation Trust, United Kingdom.

Complete Peer review History: <http://www.sdiarticle4.com/review-history/60333>

**Original Research Article**

**Received 29 June 2020**

**Accepted 05 September 2020**

**Published 08 September 2020**

### **ABSTRACT**

Lymphocystis disease has been reported worldwide in several species of freshwater fish and marine fish, naturally infected in the wild environment, or in intensive crops in farms. Nodular warty lesions of irregular surface were observed in the tegument and fins and mouth in a species of croaker (*Micropogonias furnieri*) caught in Cassino beach Rio Grande RS, Brazil and flounder (*Paralichthys orbignyanus*) caught in the city of San Clemente, Argentina. The skin lesions fragments were fixed in 20% buffered formalin, and the histological sections were stained with hematoxylin and eosin and

\*Corresponding author: E-mail: vikavet@yahoo.com.br;

Periodic Acid-Schiff (PAS), where microscopic alterations were visualized in the form of hyaline capsule with small basophilic structures in nodules and fibroblastic cells proliferation. The reported cases were based on the disease macroscopic findings characteristic of a lymphocystis disease, along with the histopathology, which confirmed the presence of the disease in the analyzed tissues.

**Keywords:** *Lymphocystis disease; viruses; marine fish; diagnosis; histopathology.*

## 1. INTRODUCTION

Lymphocystis disease is a viral disease caused by an iridovirus and one of the first viral diseases reported in fish in the 19th century, being first diagnosed in the year 1874 [1]. However, the viral agent was identified by means of electronic microscopy only in 1962 [2] and, subsequently, the virus was isolated from the lineage BF-2 [3]. Structurally, they are large icosahedral viral particles, with variable size from 120 to 340 nm in diameter, depending on the host fish species [4,5]. Although there are studies about the agent of the disease, the disease pathogenesis is still not clearly known [6], being reported as belonging to the genus Lymphocystivirus, within which is inserted the lymphocystis disease virus 1 (LCDV-1) originally isolated from the European flounder *Platichthys flesus* (Linnaeus, 1758) and from the European plaice, *Pleuronectes platessa* (Linnaeus, 1758), also included three candidates to the virus in this genus: LCDV-2, isolated from common *Limanda limanda* (Linnaeus, 1758); LCDVC, isolated from the Japanese plaice, *Paralichthys olivaceus* (Temminck and Schlegel, 1846); and LCDV-RF, isolated from the black scabbardfish, *Sebastes schlegelii* (Hilgendorf, 1880). The virus of the lymphocystis disease 1 and other related viruses are identified by means of host specificity, histopathology and profile of viral protein and DNA sequences [7].

The virus structure has stability to the pH between 6-9, being resistant to treatment with ultrasound [8], but demonstrate thermal instability, may be inactivated in Ether, glycerol, 5-iododeoxyuridine and UV treatments [1,9], in addition to the decrease of viral infectivity after freezing - thawing cycles at 20°C [3].

The lymphocytic disease has been reported worldwide in several species of freshwater fish and marine, naturally infected in the wild environment, or in intensive crops in farms [5,10-17]. The viral transmission among animals is an important fact in the spread of the disease, since it can occur horizontally through the skin and gills of fish by direct contact among them, being facilitated by traumas in handling,

parasitism and animals' aggressive behavior when maintained at high population densities, and simply by exposure in the virus presence in the water [1,18,19] and in feeding, since artemia nauplii (*Artemia* sp.) and rotifers (*Brachionus plicatilis*) may act as virus reservoirs [20,21]. The vertical form of viral transmission may also occur through infected eggs [21].

The disease although is not considered a fatal course and not be a zoonotic disease, has characteristics in fish affected that hinder their commercialization, mainly due to external lesions, where this aspect generates repulsion from the consumer, which leads to economic losses to producers [22]. These characteristics include nodular lesions on the skin of infected animals, being observed microscopically hypertrophy of fibroblasts in the dermis connective tissue, proliferating occasionally as true epithelial tumors on the body surface area [23]. The nodular lesions may be isolated or grouped, rarely being found in the internal organs. Each node represents an infected host cell, which is called lymphocyst or lymphocyst cell [24,25], usually associated to the tissue of the skin and fins, with probable viral multiplication only in fibroblastic cells [26].

The illness itself does not generate high mortalities, since the host in general recovers in a few weeks [27], however, when there is an invasion of bacteria in the lymphocyst lesion site, such infections can be fatal to the animal, already being reported a mortality rate of 90% in *Paralichthys olivaceus* after possible bacterial infection secondary to the lymphocyte disease [28].

The lymphocyst disease is often confused with neoplastic lesions or parasitary etiology being necessary a proper diagnosis to take appropriate prophylactic measures in the spread of the disease, since the transmission occurs quickly, and may cause serious mortalities without identifying the cause correctly. Here two cases are reported of the disease in different places, with some similar climatic characteristics, which may be a relevant point in their occurrence. Both

species are considered to have potential for aquaculture, with studies showing good condition factors for *M. furnieri* raised in net tanks [29] and the flounder, *P. orbignyanus*, is already a known species in the commercial and recreational area, inhabiting marine and estuarine waters from Brazil (Rio de Janeiro) to Argentina (San Matías Golfo) [30]. (Figueiredo e Menezes, 2000)

## 2. MATERIALS AND METHODS

Nodular warty lesions were observed of irregular surface in the tegument and fins and mouth in a species of wild croaker (*Micropogonias furnieri*) measuring 19 cm in length and 70.4 g in weight (Fig. 1) a group of animals kept in Cassino beach Rio Grande RS, Brazil and wild flounder

(*Paralichthys orbignyanus*) measuring 36 cm in length and 575 g in weight, captured in the city of San Clemente, in Buenos Aires, Argentina (Fig. 2).

The animals were euthanized in benzocaine hydrochloride (300 mg/L) and the autopsy was performed for material collection for histopathological analysis. The skin lesions fragments were fixed in 20% buffered formalin. The tissue samples were subjected to histological processing (LEICA TP 1020) and included in paraplast. The tissue sections were performed to a thickness of 5 $\mu$  in the microtome Leica RM2245. The histological sections were stained with hematoxylin and eosin and periodic acid-Schiff (PAS).



Fig. 1. Specimen of *Micropogonias furnieri* with warty aspect nodular lesions in the tegument and fins (arrows)

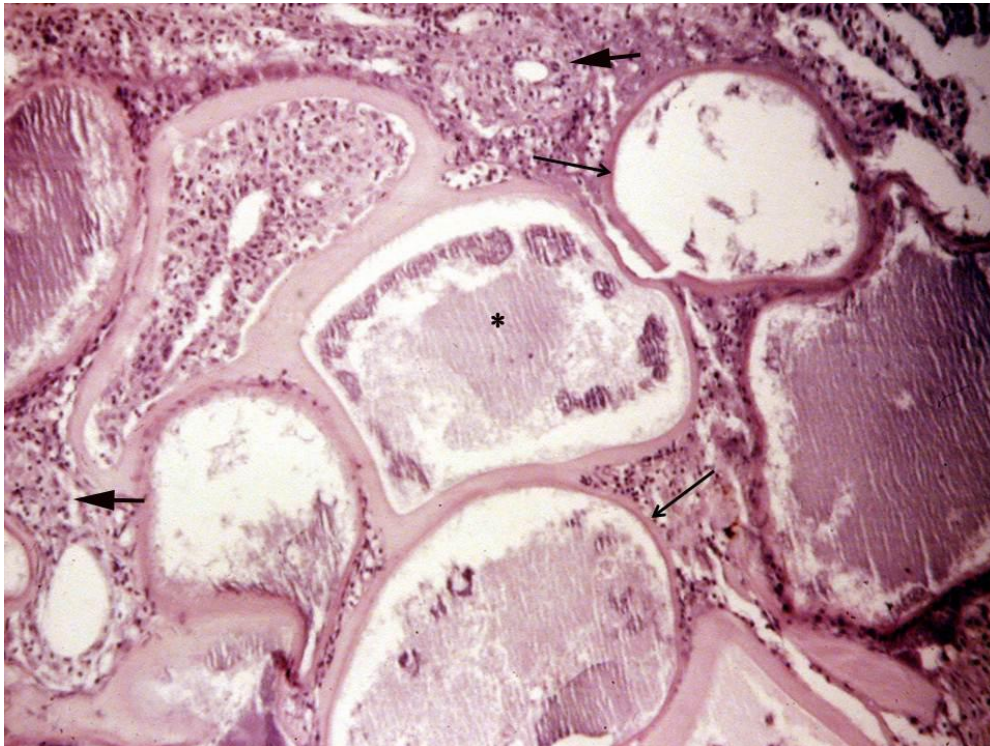


Fig. 2. Specimen of *Paralichthys orbignyanus* nodular, warty aspect and congestive lesions in the oral region (arrow)

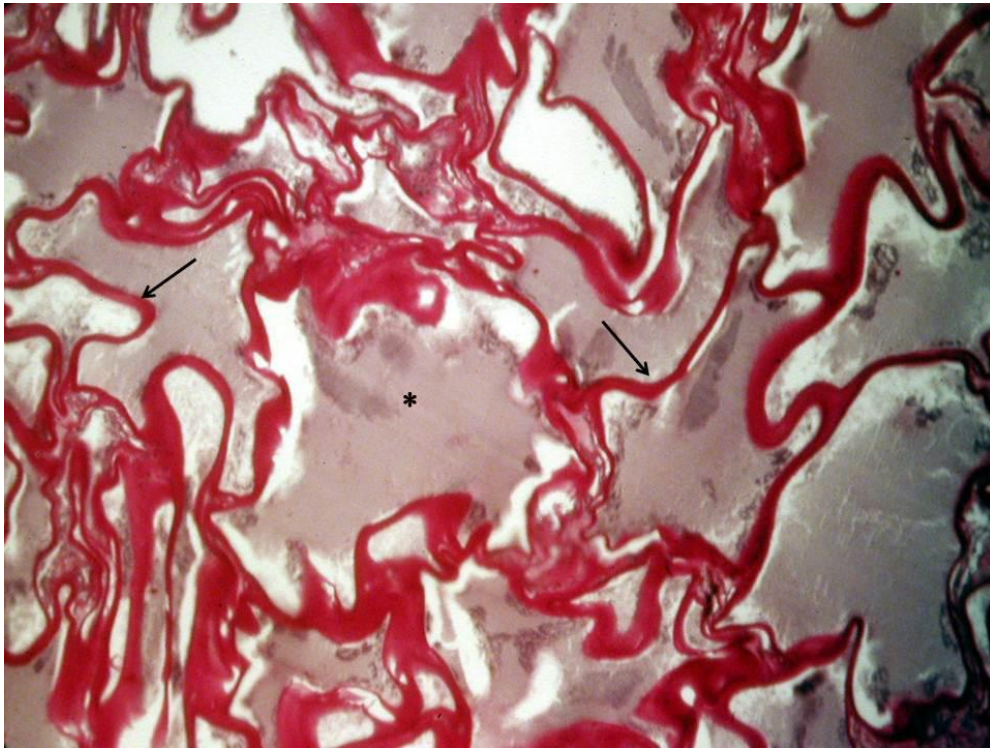
### 3. RESULTS AND DISCUSSION

In the histopathological examination, microscopic changes were observed in the form of hyaline capsule with small basophilic structures in nodules and proliferation of fibroblastic cells (Fig. 3). These cases of LCDV were diagnosed in wild animals which imply that the virus is found in the natural environment. These cases of LCDV were diagnosed in wild animals which imply that the virus is found in the natural environment. This fact is reported in the literature that most cases are of animals raised in aquaculture farms [5,6,8,17,31]. Macroscopically, the animals had nodular lesions measuring approximately 1-2 mm, warty aspect and irregular surface, with coloring cream to reddish (Figs. 1 and 2), each node representing a cell infected by LCDV, also called lymphocyst or lymphocyst cell [25]. The infected cell staining (nodules), or infected clustered cells may vary when the dermis epithelial tissue is rich in chromatophores, which can modify the coloring to darker shades [32].

The virus shows affinity for replication in dermal fibroblasts, resulting in hypertrophied cells mainly on the dermis and flippers [26], which can be evidenced in the lesion microscopic characteristics (Fig. 3). In addition to the fibroblasts, some authors suggest other cell types target of infection, such as hepatocytes and cells of mononuclear phagocytic system [33], not being frequent cases of localized lesions in the eyes and internal organs with systemic involvement [1], which has been discussed by some authors that describe the systemic involvement being considered only in experimental cases, while other authors reported the occurrence of disease by natural means [34,35,36]. In a study on the virus tissue location after experimental infection intravenously, the hypothesis was raised that the distribution of antigen in blood cells was negative for the presence of LCDV, revealing that the virus could infect red blood cells which can only infect certain types of leukocytes, which would probably cause the entry of the virus structure in the bloodstream, generating a systemic infection [37].



**Fig. 3. Skin specimen of *Micropogonias furnieri* with multiple cystic formations, thick homogeneous capsule (arrows) and basophilic small structures (\*) with proliferation of fibroblasts surrounding the cystic structures (thick arrow). H-E. 10X**



**Fig. 4.** Skin of *Paralichthys orbignyanus* specimen where the same cystic structures are observed in croaker *Micropogonias furnieri* with presence of hyaline capsule strongly homogeneous PAS+ (arrows) inside the nodules multiple small basophilic structures are observed (\*). PAS. 40X

The cytoplasm undergoes changes, developing intracytoplasmic basophilic inclusion bodies as dense vacuolated bodies [26], which can be seen in Fig. 3. This cell standard has already been reported in other studies [38], which indicate that the histopathology allows us a diagnosis of the disease characterized by fibroblastic cells with basophilic cytoplasm and prominent nuclei, discarding the differential diagnosis of a neoplastic lesion or parasitic etiology. The presence of hyaline capsule can also be evidenced by means of the Periodic Acid-Schiff (PAS) technique (Fig. 4), where a thick hyaline capsule can be observed circling the infected hypertrophied fibroblast, which according to some authors can be seen especially in mature lymphocyst cells [26]. The disease molecular diagnosis, although provides accuracy in the agent identification, represents a method that is more expensive and, depending on the virus protein profiles, needs more time for the diagnosis conclusion [26].

The two cases here reported in different regions, but with similar climatic characteristics, raises an

important point in the occurrence of the disease, since some authors have already reported the importance of temperature in the virus persistence on the Japanese plaice tissue, where it was noted that at temperatures of 10°C, LCDV may persist for long periods on the fish epidermis in the form of a subclinical infection, coming to demonstrate clinical signs and presence of lymphocyst cells at temperatures of 20°C, considered ideal for the virus infectivity [39]. Inadequate conditions in cultivation may also influence in the disease clinical manifestation, such as high densities in the tanks, excessive manipulation, low salinity, low dissolved oxygen, nutritional deficiencies and water biological pollution [18,25,40,41,42, 43,44,45,46], which is a point to be considered, since the fish could be in stress situations in the tanks where they were being kept.

#### 4. CONCLUSION

The reported cases were based on the clinical and macroscopic aspects of lymphocyst disease, along with the histopathology, which confirmed

the presence of the disease in the analyzed tissues, demonstrating that it is a method that is fast and effective, not being necessary to resort to other methods for a conclusive diagnosis of the disease.

## ACKNOWLEDGEMENTS

This study was supported by the research funds from MCT/CNPq- Project #301245/2016-09 MCT/CNPq/CT- Agronegocio/MPA Public Notice 036/2009 Project #308013/2009-3, Coordenação de Aperfeiçoamento de Pessoal de Nível Superior (CAPES), and Ministério da Pesca e Aquicultura (MPA).

## COMPETING INTERESTS

Authors have declared that no competing interests exist.

## REFERENCES

1. Wolf K. Lymphocystis disease. In: Wolf K, editor. Fish Viruses and Fish Viral Diseases. Ithaca: Cornell University Press; 1988.
2. Walker R. Fine structure of lymphocystis disease virus in fish. Virology. 1962;18: 503-505.
3. Wolf K. Experimental propagation of lymphocystis disease of fishes. Virology. 1962;18:249-256.
4. Tidona CA, Darai G. Lymphocystis disease virus (Iridoviridae). In: Granoff A, Webster RG, editors. Encyclopedia of Virology. 2<sup>nd</sup> Ed. Academic Press, New York; 1999.
5. Paperna I, Vilenkin M, de Matos AP. Iridovirus infections in farm-reared tropical ornamental fish. Diseases of Aquatic Organisms. 2001;48:17-25.
6. Zhang QY, Ruan HM, Li ZQ, Yuan XP, Gui JF. Infection and propagation of lymphocystis virus isolated from the cultured flounder *Paralichthys olivaceus* in grass carp cell lines. Diseases of Aquatic Organisms. 2003;57:27-34.
7. Jancovich JK, Chinchar VG, Hyatt A, Miyazaki T, Williams T, Zhang QY. Family Iridoviridae. In: King AMQ, Adams MJ, Carstens EB, Lefkowitz E, editors. Virus Taxonomy: Ninth Report of the International Committee on Taxonomy of Viruses. Elsevier Academic Press, San Diego; 2012.
8. Walker DP, Hill BJ. Studies on the culture assay of infectivity and some *in vitro* properties of lymphocystis virus. Journal of General Virology. 1980;51:385-395.
9. Iwamoto R, Hasegawa O, LaPatra S, Yoshimizu M. Isolation and characterization of the Japanese flounder (*Paralichthys olivaceus*) lymphocystis disease virus. Journal of Aquatic Animal Health. 2002;14:114-123.
10. Anders K. Lymphocystis disease of fishes. In: Ahne W, Kurstak D, editors. Viruses of Lower Vertebrates. Springer-Verlag, Berlin; 1989.
11. Marcogliese DJ, Fournier M, Lacroix A, Cyr DG. Non-specific immune response associated with infections of lymphocystis disease virus in American plaice, *Hippoglossoides platessoides* (Fabricius). Journal of Fish Diseases. 2001;24:121-124.
12. Bunkley-Williams L, Williams EH, Phelps RP. Does lymphocystis occur in pacora, *Plagioscion surinamensis* (Sciaenidae), from Colombia? Acta Tropica. 2002;82:7-9.
13. Gusmão E, Zacarias R, Brahm J, Berteaux R, Sampaio L. Linfocistes em *Paralichthys orbignyanus* (Pisces, Pleuronectiformes, Paralichthyidae) cultivado no sul do Brasil. Biociencias. 2006;14:225-227.
14. Sheng XZ, Zhan WB, Wang Y. Whitespotter puffer *Arothron hispidus*, a new host for lymphocystis in Qingdao Aquarium of China. Diseases of Aquatic Organisms. 2007;75:23-28.
15. Hossain M, Song JY, Kitamura SI, Jung SJ, Oh MJ. Phylogenetic analysis of lymphocystis disease virus from tropical ornamental fish species based on a major capsid protein gene. Journal of Fish Diseases. 2008;31:473-479.
16. Xu L, Feng J, Huang Y. Identification of lymphocystis disease virus from paradise fish *Macropodus opercularis* (LCDVPF). Archives of Virology. 2014;159:2445-2449.
17. Huang X, Huang Y, Xu L, Wei S, Ouyang Z, Feng J, Quin Q. Identification and characterization of a novel lymphocystis disease virus isolate from cultured grouper in China. Journal of Fish Diseases. 2015; 38:379-387.
18. Bowser PR, Wooster GA, Getchell RG. Transmission of walleye dermal sarcoma and lymphocystis via waterborne exposure. Journal of Aquatic Animal Health. 1999;11:158-161.
19. Kvitt H, Heinisch G, Diamant A. Detection and phylogeny of Lymphocystivirus in sea bream *Sparus aurata* based on the DNA

- polymerase gene and major capsid protein sequences. *Aquaculture*. 2008;275:58-63.
20. Cano I, Lopez-Jimena B, Garcia-Rosado E, Ortiz-Delgado JB, Alonso MC, Borrego JJ, Sarasquete C, Castro D. Detection and persistence of Lymphocystis disease virus (LCDV) in *Artemia* sp. *Aquaculture*. 2009;291:230-236.
  21. Cano I, Valverde EJ, Garcia-Rosado E, Alonso MC, Lopez-Jimena B, Ortiz-Delgado JB, Borrego JJ, Sarasquete C, Castro D. Transmission of lymphocystis disease virus to cultured gilthead seabream, *Sparus aurata* L., larvae. *Journal of Fish Diseases*. 2013;36:569-576.
  22. Masoero L, Ercolini C, Caggiano M, Rossa A. Osservazioni preliminary sulla linfocisti in una maricoltura intensive italiana. *Rivista Italiana di Piscicoltura e Ittiopatologia*. 1986;21:70-74.
  23. Samalecos CP. Analysis of the structure of fish lymphocystis disease virions from skin tumors of *Pleuronectes*. *Archives of Virology*. 1986;91:1-10.
  24. Gonzalez de Canales ML, Muñoz-Cueto JA, Arellano J, Garcia-Garcia A, Sarasquete C. Histological and histochemical characteristics of the lymphocystis disease in gilthead sea bream, *Sparus aurata*, L. from the South-Atlantic coast of Spain. *European Journal of Histochemistry*. 1996;40:143-152.
  25. Paperna I, Sabnai I, Colorni A. An outbreak of lymphocystis in *Sparus aurata* L. in the Gulf of Aqaba, Red Sea. *Journal of Fish Diseases*. 1982;5:433-437.
  26. Hossain M, Oh M-J. Histopathology of marine and freshwater fish Lymphocystis Disease Virus (LCDV). *Sains Malaysiana*. 2011;40(10):1049-1052.
  27. Roberts RJ. Experimental pathogenesis of lymphocystis in the plaice, *Pleuronectes platessa*. In: Page LA, editor. *Wildlife Diseases*. Plenum Press, New York; 1976.
  28. Havikrishnan R, Balasundaram C, Heo MS. Effect of probiotics enriched diet on *Paralichthys olivaceus* infected by lymphocystis disease virus (LCDV). *Fish and Shellfish Immunology*. 2010;29:868-874.
  29. Sampaio LA, Burkert D, Santos FM, Streit Júnior DP, Tesser MB. Avaliação do potencial da criação de corvine (*Micropogonias furnieri*) em tanque-rede no estuário da Lagoa dos Patos, Brasil. *Atlântica*, Rio Grande. 2011;33(1):65-71.
  30. Figueiredo JL, Menezes NA. Manual de peixes marinhos do sudeste do Brasil. Museu de Zoologia, Universidade de São Paulo, São Paulo; 2000.
  31. Roberts, RJ. *Fish Pathology*. Blackwell Publishing Ltd.; 2012.
  32. Smail DA, Munro ALS. The virology of teleosts. In: Roberts RJ, editor. *Fish pathology*. 4th ed. W.B. Saunders, Edinburgh; 2012.
  33. Valverde EJ, Borrego JJ, Sarasquete MC, Ortiz-Delgado JB, Castro D. Target organs for lymphocystis disease virus replication in gilthead seabream (*Sparus aurata*). *Vet Res*. 2017;48:21.
  34. Huzinga HW, Cosgrove GE. Surface and visceral lymphocystis disease in a white crappie, (*Promoxis annularis*). *J. Wildl. Dis*. 1973;9:349-351.
  35. Smith FG. Lymphocystis disease in *Cynoscion nothus*, *Cynoscion regalis* and *Stellifer lanceolatus* from Georgia Estuaries. *Proc. 26<sup>th</sup> Ann. Conf. Southeast Assoc. of Game and Fish Comm*. 1973; 598-608.
  36. Dukes TW, Lawler AR. The Ocular Lesions of Naturally Occurring Lymphocystis in Fish. *Can. J. Comp. Med*. 1975;39:406-410.
  37. Sheng X, Wu R, Tang X, Xing J, Zhan W. Tissue Localization of Lymphocystis Disease Virus (LCDV) Receptor-27.8 kDa and Its Expression Kinetics Induced by the Viral Infection in Turbot (*Scophthalmus maximus*). *Int. J. Mol. Sci*. 2015;16:26506-26519.
  38. Dunbar CE, Wolf K. The cytological course of experimental lymphocystis in the bluegill. *Journal of Infectious Diseases*. 1966;116:466-472.
  39. Hossain M, Kim SR, Kitamura SI, Kim DW, Jung SJ, Nishizawa T, Yoshimizu M, Oh MJ. Lymphocystis disease virus persists in the epidermal tissues of olive flounder, *Paralichthys olivaceus* (Temminch & Schlegel), at low temperatures. *Journal of Fish Diseases*. 2009;32:699-703.
  40. Berthiaume L, Heppel J, Desy M, Leblanc L, Lallier R, Bailey R, Dutil J-D. Manifestation of lymphocystis disease in American plaice (*Hippoglossoides platessoides*) exposed to low salinities. *Canadian Journal of Fisheries and Aquatic Sciences*. 1993;50:430-434.
  41. Sindermann CJ. Pollution and infectious diseases. In: Sindermann CJ, editor.

- Ocean Pollution: Effects on Living Resource and Humans. CRC Press, Boca Raton; 1996.
42. Vethaak AD, Jol JG. Disease of flounder *Platichthys flesus* in Dutch coastal and estuarine waters, with particular reference to environmental stress factors. I. Epizootiology of gross lesions. Diseases of Aquatic Organisms. 1996;26: 81-97.
43. Møllergaard S, Nielsen E. Epidemiology of lymphocystis, epidermal papilloma and skin ulcers in common dab *Limanda limanda* along the west coast of Denmark. Diseases of Aquatic Organisms. 1997;30: 151-163.
44. Austin B. The effects of pollution on fish health. Journal of Applied Microbiology Symposium Supplement. 1999;85:234-242.
45. Grygiel W. Synoptic survey of pathological symptoms in herring (*Clupea harengus*) and sprat (*Sprattus sprattus*) in the Baltic Sea. ICES Journal of Marine Science. 1999;56:169-174.
46. Kitamura S-I, Ko J-Y, Lee W-L, Kim S-R, Song J-Y, Kim D-K, Jung S-J, Oh M-J. Seasonal prevalence of lymphocystis disease virus and aquabirnavirus in Japanese flounder, *Paralichthys olivaceus*, and blue mussel, *Mytilus galloprovincialis*. Aquaculture. 2007;266:26-31.

© 2020 Pedrosa et al.; This is an Open Access article distributed under the terms of the Creative Commons Attribution License (<http://creativecommons.org/licenses/by/4.0>), which permits unrestricted use, distribution, and reproduction in any medium, provided the original work is properly cited.

*Peer-review history:*

*The peer review history for this paper can be accessed here:*  
<http://www.sdiarticle4.com/review-history/60333>