



## Missed Iatrogenic Cervical Esophageal Injury: A Favorable Result in a Late Case

Misauq Mazcari<sup>1\*</sup>, Ambreen Abid<sup>1</sup>, Tanveer Ahmad<sup>1</sup>, Nazish Sikander<sup>1</sup>  
and Pratikshya Thapaliya<sup>1</sup>

<sup>1</sup>Department of Thoracic Surgery, Jinnah Postgraduate Medical Centre, Karachi, Pakistan.

### Authors' contributions

This work was carried out in collaboration among all authors. Author MM has carried out the manuscript writing, drafting, literature search and prepared the final draft. Author AA completed the critical analysis of draft and literature search. Authors NS and PT have done the literature search. Author TA gave the final approval to be published and contributed in literature search. All authors read and approved the final manuscript.

### Article Information

#### Editor(s):

(1) Dr. José Francisco de Sales Chagas, Sao Leopoldo Mandic Medical School, Brazil.

#### Reviewers:

(1) Meer Chisthi, Government Medical College Thiruvananthapuram, India.

(2) Mukul Patar, Gauhati Medical College and Hospital, India.

Complete Peer review History: <http://www.sdiarticle4.com/review-history/60647>

Case Report

Received 19 June 2020  
Accepted 24 August 2020  
Published 01 September 2020

### ABSTRACT

Missed iatrogenic cervical esophageal injury after thyroidectomy is a rare complication. Post-operative painful deglutition, subcutaneous emphysema or local swelling should raise the alarm. Seven days after thyroidectomy, a patient was referred to us with copious purulent discharge and saliva draining from cervical wound. Cervical incision was taken down; wound irrigated and kept open for dressings. Focused wound management along with enteral feeding via feeding jejunostomy was initiated. Esophagoscopy was done in the second week and proximal edge of defect was identified. During the third week, when wound was clean and patient had gained her lost weight back, mucosal and muscular layers were repaired with interposition flap between esophagus and trachea. On seventh post-repair day esophagogram was normal. Patient was discharged on semisolids. Six weeks postoperatively, endoscopy and dilation was done for grade II dysphagia. Six months later, patient remains symptom free.

*Keywords: Cervical esophageal perforation; iatrogenic; thyroidectomy; mortality.*

\*Corresponding author: E-mail: [misauq229@gmail.com](mailto:misauq229@gmail.com);

## 1. INTRODUCTION

Although esophageal injuries are uncommon with overall incidence of 3 %, they have a potential for life threatening outcomes [1]. Iatrogenic injuries are the most common cause of cervical esophageal perforation [2] and can occur during procedures such as endoscopy, endotracheal intubation, tracheostomy or surgeries involving the neck [2]. Thyroidectomy itself is one of the least common causes with only seven cases reported [3].

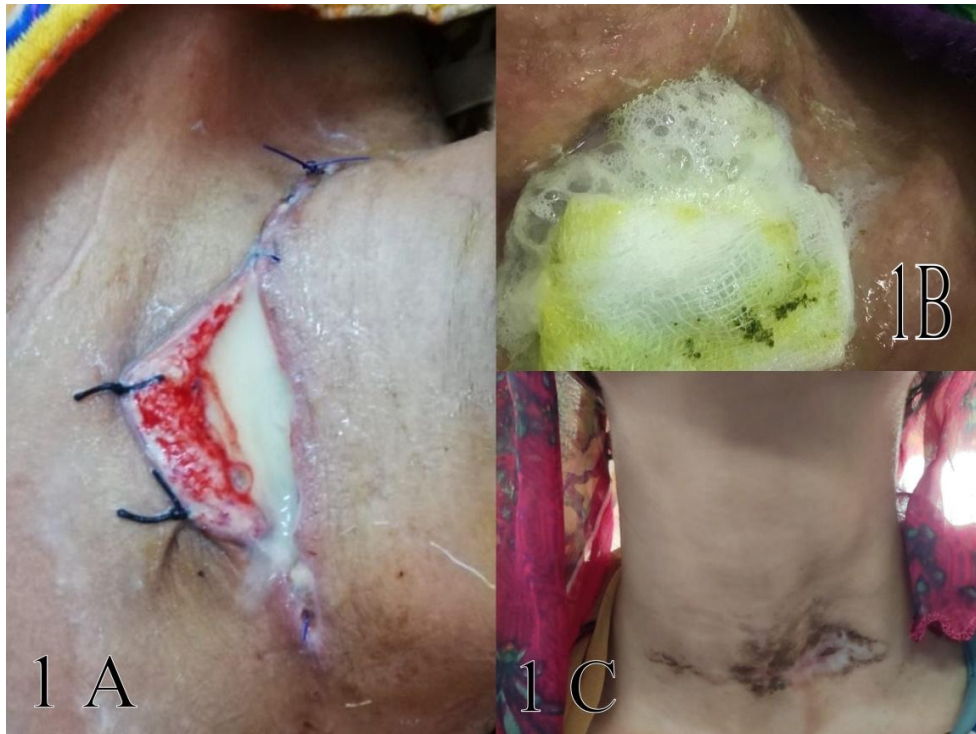## 2. PRESENTATION OF CASE

A 23 year old teacher was referred to us by the operating surgeon seven days after a thyroidectomy. On presentation she was severely dehydrated, febrile, weak and unable to vocalize. The cervical wound was showing a pool of purulent secretions mixed with saliva and food particles continuously streaming down her neck.

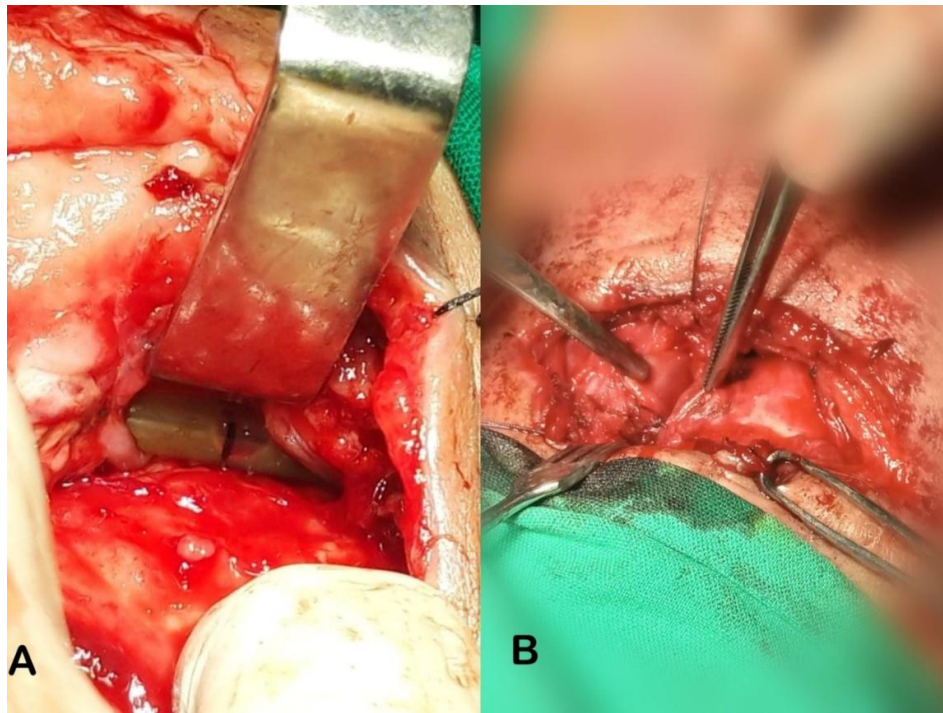
Cervical incision was completely taken down, wound washed and irrigated with copious normal

saline and kept open for daily dressings. There were silk sutures present in the wound. On further exploration it was found that the lower edge of the esophageal laceration was sutured with the lateral wall of trachea. Edema, inflammation and thick purulent flakes were present all over the wound and extended deep in the prevertebral region. Sutures were removed, wound was irrigated and kept open for dressing. Patient was made nil by mouth, pus cultures was obtained, empirical antibiotics were started, intravenous fluids initiated and a feeding jejunostomy was fashioned for enteral feeding.

In the second week when the wound was clean, we proceeded with rigid esophagoscopy under general anesthesia to determine the proximal edge of esophageal injury. A defect in the anterolateral wall of the cervical esophagus about 2.8 cm in length at C 5 and C 6 level was identified, with only the posterior esophageal wall intact. The proximal edge was marked with a prolene stitch and the defect was carefully stented with a nasogastric tube.



**Fig. 1A. Initial presentation of wound with discharge, 1B. Salivary discharge from wound, 1C. Healed wound**



**Fig. 2A. Wound exploration with nasogastric tube in situ, 2B. Layered repair of esophagus**

High caloric diet through the feeding jejunostomy and parenteral route was continued to help gain her weight (5 kg). On the 19<sup>th</sup> day of admission the wound was explored with intent to repair the defect. Esophageal edges were mobilized carefully, and the defect was repaired in two layers over a thin nasogastric tube. Mucosal layer was repaired with interrupted 3/0 vicryl and the muscular layer was repaired with 2/0 interrupted silk sutures and interposition muscle flap was placed between the esophagus and trachea.

On seventh day of repair, an esophagogram was found to be normal. Patient tolerated semisolids well and was discharged. She presented six weeks later with grade II dysphagia for which endoscopy and dilation was done. Six months post repair, patient remains symptom free.

### 3. DISCUSSION

Cervical esophageal perforation constitutes 57 % of all esophageal perforations [1]. Seventy percent of them are iatrogenic [2,4]. Iatrogenic injury results from sharp foreign bodies, interventional procedures such as endoscopy or while endotracheal intubation of difficult patients or procedures for cervical spine or thyroid [2,4]. These patients present with pain in neck or

chest, stiffness or pain in neck movements, dysphagia and fever. On examination, subcutaneous emphysema can be appreciated initially on neck and later on chest. Change of voice may also be appreciated [2,4,5,6,7,8,9,10].

All suspected and symptomatic patients should be investigated early [4,11]. Radiographs of neck and chest with presence of air in prevertebral plan on a lateral view is initially discovered [4,10,11]. Contrast esophagogram is investigation of choice as it confirms the diagnosis, defines site, extent of injury and is also beneficial after surgical repair [5,7,8,9,10,12]. Role of endoscopy is debatable as it allows visualization of perforation but may also enlarge it if not performed carefully [2,5,9,11]. CT scan with contrast is done when esophagogram is not possible or investigations do not substantiate in highly suspected cases. It also identifies other pathologies [2,4,5,8,9,11]. CT scan has a false negative rate of 1% vs 10% seen in esophagogram [1,3,5,13].

When esophageal injury is suspected after thyroidectomy, treatment should commence within 24 hours of the event [1,2,3,6]. Management can be conservative for tears less than 2 cm without mediastinal contamination [2,4]. Focused, aggressive management is

required in cases of larger injuries recognized late such as in this case to avoid progressive necrosis of esophagus and risk of extension to mediastinum. Wounds must be widely opened and drained with irrigation to remove visible purulent debris.

Intravenous broad spectrum antibiotics, fluid resuscitation and parenteral nutrition play a vital role [3,4,5,8,10,14]. A feeding jejunostomy to address adequate caloric intake and avoid fluid and electrolyte imbalance should be started early [2,4,5,13]. The goal of this focused management protocol is to help achieve a clean wound with healthy granulation tissue so that the esophageal defect be effectively repaired [14].

Primary surgical repair with neck drainage remains treatment of choice if performed within 24 hours of injury [2,4,5,13,14]. It can be done in two layers with or without reinforcement [4,5,9,10]. Contained cervical perforation can be treated with drainage alone procedure and conservative management [11]. Esophagectomy with reconstruction with or without feeding jejunostomy may be required for large defects, extensive mediastinal contamination and esophageal necrosis [2,5,9]. Our strategy in this case had been to avoid resorting to an esophagectomy which carries its own morbidity and mortality.

Esophageal perforations have around 15-28% mortality [4,12,14]. Cervical esophageal perforations have a lower mortality rate around 6 to 8 % [2,3,4,11]. Morbidity and mortality are dependent on early diagnosis and early treatment [2]. Esophageal perforations treated within 24 hours have a mortality rate of 14% as compared to 27% when presented and treated after 24 hours [4,12,14].

#### 4. CONCLUSION

Late recognition of iatrogenic cervical esophageal injury poses a unique management challenge to a thoracic surgeon. Wound drainage must be early to avoid esophageal necrosis and mediastinitis. A focused management protocol and aggressive supportive care in a dedicated center to achieve repair is still possible with low postoperative morbidity.

#### CONSENT

Informed and written consent was taken from patient for publication of this case report and accompanying images.

#### ETHICAL APPROVAL

Case reports are exempted from ethical approval as per our institutional review board policy.

#### COMPETING INTERESTS

Authors have declared that no competing interests exist.

#### REFERENCES

1. Vázquez-Rodríguez J, Pelet del Toro N, García-Rodríguez O, et al. Traumatic esophageal perforation in Puerto Rico Trauma Hospital: A case-series. *Annals of Medicine and Surgery*. 2019;44:62-67. DOI: 10.1016/j.amsu.2019.06.01
2. Aghajanzadeh M, Porkar N, Ebrahimi H. Cervical esophageal perforation: A 10-year clinical experience in North of Iran. *Indian Journal of Otolaryngology and Head & Neck Surgery*. 2014;67(S1):34-39. DOI: 10.1007/s12070-014-0737-z
3. Maupoey Ibáñez J, Ballester Pla, N, García-Domínguez R, Vaqué Urbaneja J, Mingol Navarro F. Surgical Management of a Complete Section of the Oesophagus During Total Thyroidectomy. *Cirugía Española (English Edition)*. 2017;95(2): 118-120. 10.1016/j.cireng.2017.03.004
4. Chirica M, Kelly M, Siboni S, Aiolfi A, Riva C, Asti E, et al. Esophageal emergencies: WSES guidelines. *World Journal of Emergency Surgery*. 2019;14(1). DOI: 10.1186/s13017-019-0245-2
5. Abila A, Nditika M, Kipkemoi R, Ondigo S, Khwa-Otsyula B. Primary repair of esophageal perforation: Case report. *International Journal of Surgery Case Reports*. 2020;71:159-162. DOI: 10.1016/j.ijscr.2020.04.026
6. Park A, Yoo Y, Choi J, Chung E. Usefulness of vacuum-assisted closure therapy in the treatment of esophageal perforation following thyroidectomy. *Korean Journal of Otorhinolaryngology-Head and Neck Surgery*. 2017;60(5):252-256. DOI: 10.3342/kjorl-hns.2016.17342
7. Ward N, Lee C, Lee J, Sloan D. Esophageal fistula complicating thyroid lobectomy. *Journal of Surgical Case Reports*. 2015;2015(1):rju136-rju136. DOI: 10.1093/jscr/rju136
8. Yu C, Chien C, Hsieh P, Chien R. Cervical esophageal perforation during

- endoscopic ultrasonography: A retrospective evaluation of frequency, outcome, and patient management. *Advances in Digestive Medicine*. 2018; 5(3):93-97.  
DOI: 10.1002/aid2.13085
9. Eroğlu A. Minimally invasive management of esophageal perforation. *The Turkish Journal of Thoracic and Cardiovascular Surgery*. 2018;26(3):496-503.  
DOI: 10.5606/tgkdc.dergisi.2018.15354
10. Sudarshan M, Cassivi S. Management of traumatic esophageal injuries. *Journal of Thoracic Disease*. 2019;11(S2):S172-S176.  
DOI: 10.21037/jtd.2018.10.86
11. Mavroudis C, Kucharczuk J. Acute management of esophageal perforation. *Current Surgery Reports*. 2013;2(1).  
DOI: 10.1007/s40137-013-0034-x
12. Lambert R, Angmörterh S, Benjamin M, Gonzalez M, Aboagye S, Ofori E. Esophageal perforation by tilapia fish bone ingestion – A case report. *International Journal of Surgery Case Reports*. 2020;71: 23-26.  
DOI: 10.1016/j.ijscr.2020.04.054
13. Mammadov E, Alim A, Eliçevik M, Celayir S. Traumatic upper cervical esophageal perforation in childhood with door handle. *Annals of Pediatric Surgery*. 2011;7(1):25-26.  
DOI:10.1097/01.xps.0000393088.31815.6d.
14. Puertaviciente A, JimÉnez P., López M, Nisa F, Velasco G, Álvarez, J et al. Management of Esophageal Perforation: 28-Year Experience in a Major Referral Center. *The American Surgeon*. 2018; 84(5):684-689.  
DOI: 10.1177/000313481808400520

© 2020 Mazcuri et al.; This is an Open Access article distributed under the terms of the Creative Commons Attribution License (<http://creativecommons.org/licenses/by/4.0>), which permits unrestricted use, distribution, and reproduction in any medium, provided the original work is properly cited.

*Peer-review history:*  
*The peer review history for this paper can be accessed here:*  
<http://www.sdiarticle4.com/review-history/60647>