



## **Assessment of the Dermal Acute Irritation Potential of Natural Veterinary Medicine Minyak Rajas in Albino Rabbits**

**I Made Merdana<sup>1\*</sup>, Anak Agung Gde Arjana<sup>2</sup>, Sri Kayati Widyastuti<sup>1</sup>, Tisa Tetrania<sup>1</sup>, Ketut Budiassa<sup>1</sup>, Luh Made Sudimartini<sup>1</sup> and I Wayan Sudira<sup>2</sup>**

<sup>1</sup>Department of Veterinary Clinic, Laboratory of Veterinary Pharmacy and Pharmacology, Faculty of Veterinary Medicine, Udayana University, Jl. P.B. Sudirman No.1, Denpasar, Bali-80234, Indonesia.

<sup>2</sup>Department of Veterinary Basic Science, Faculty of Veterinary Medicine, Udayana University, Jl. P.B. Sudirman No.1, Denpasar, Bali-80234, Indonesia.

### **Authors' contributions**

All authors had actively contributed from the beginning to the end of the research. Authors IMM and AAGA designed and supervised the research. Authors SKW, TT and LMS carried out research and managed the literature searches. Authors IWS, KB and IMM performed the results analyzed, drafted and completed the manuscript. All authors read and approved the final manuscript.

### **Article Information**

DOI:10.9734/JPRI/2020/v32i1030489

#### **Editor(s):**

(1) Rafik Karaman, Al-Quds University, Jerusalem.

#### **Reviewers:**

(1) Seema Venkatrao Patterwar, Sanjivani Institute of Pharmacy and Research, India.

(2) R. Velusamy, Tamil Nadu Veterinary and Animal Sciences University, India.

Complete Peer review History: <http://www.sdiarticle4.com/review-history/58243>

**Original Research Article**

**Received 27 May 2020**

**Accepted 13 June 2020**

**Published 23 June 2020**

### **ABSTRACT**

**Aims:** This study was designed to assess the potential for acute dermal irritation of natural veterinary medicine Minyak Rajas (produce by Songgolangit Persada Limited Company, Bali, Indonesia) in albino rabbits. It is a rather thick liquid which contains various medicinal herbal extracts, formulated with effective microorganism technology. This medicine is effective in the treatment of skin infections and inflammation, wounds, intestinal worms and digestive disorder. Additionally, it works for game fowl muscle strengthening.

**Place and Duration of Study:** This study was conducted at the Veterinary Pharmacy and Pharmacology Laboratory, Faculty of Veterinary Medicine, Udayana University, between April 2020 and May 2020.

**Methodology:** Experimental animals used were three male albino rabbits (*Oryctolagus cuniculus*) in healthy conditions and weighing of >2 Kg. Test procedures followed the guidelines of

\*Corresponding author: E-mail: imade\_merdana@unud.ac.id;

Organisation for Economic Cooperation and Development, and chemicals used were applied in a single dose of 0.5 ml on animal skins, with untreated skin as a control.

**Results:** Very slight erythema was found after the Minyak Rajas application and the lesion was about 48 hours. Overall, no severe erythema, edema or other skin lesions were observed. According to the Amended Draize system, the Primary Irritation Indexes of 0.16 is categorized as non-irritating.

**Conclusion:** We conclude that the natural veterinary medicine of Minyak Rajas is safe to be used.

**Keywords:** Skin irritation; natural veterinary medicine; Minyak Rajas.

## 1. INTRODUCTION

The development of natural medicines has been achieved extensively in the fields of cosmetics and drugs. Minyak Rajas is a new natural veterinary medicine specially formulated from various herbs using effective microorganism technology. This formulation consists of *Oleum cocos* 76%, *Zingiberis rhizome* 1.1%, *Languatis rhizome* 1%, *Curcuma domesticae rhizome* 1.2%, *Curcuma exanthorrhiza rhizome* 1.2%, *Imperatae rhizome* 0.4%, *Piperis bethium folium* 0.7%, *Curcuma aegeruginosae rhizome* 1.1%, and *Zingiberis purpurei rhizome* 1.1%. According to research all of these herbs are reported to have pharmacological effects. The active compound in *Oleum cocos* acts as an anti-inflammatory, antipyretic, analgesic and wound medicine [1]. *Zingiber spp.* contains essential oils, zingiberin, olericin as antiseptic, anti-fungal, anti-inflammatory, antibacterial, analgesic and antioxidant [2-4]. *Rhizome languatis* contain active ingredients ethyl cinnamate and quercetin as an anti-inflammatory, antioxidant, anticancer and antiaging agent [5-7]. *Curcuma spp* contains curcuminoids and essential oils [8,9] as antiseptic, analgesic, antifungal and anti-inflammatory [10-12]. *Imperatae rhizome* contains alkaloids, flavonoids, phenolics, triterpenoids, tannin glycosides, saponins and steroids as anti-inflammatory and antiplatelet [13,14]. *Piperis betle* folium contains monoterpane, sesquiterpane cineol and eugenol [15] as antibacterial, antiparasitic, antifungal and antioxidant [16,17]. Organoleptically, Minyak Rajas is known to have rather thick liquid texture, brownish-yellow in color, a distinctive aroma of herbal spice, with a bitter taste and a little spicy. It is also known that this formula has a pH of 5-6 and a density of 923 mg/ml.

Minyak Rajas is infused through the dermal route to relieve skin diseases and inflammations, intestinal worms, and digestive disorder. Therapeutically, the oil can cause unwanted side effects such as skin toxicity which occurs after

been exposed to chemicals with high reception ability [18,19]. Irritations or toxic effects are caused by many substances, some of them are medicinal chemicals, phototoxic materials, phytochemical, air irritants and others [20]. For this reason, it was important to conduct the toxicity test toward each new drug to estimate the damage degree which maybe appear. Generally, the toxicity test aims to determine the unwanted side effects of the drug. The toxicological screening can provide the scientific facts of the therapeutic or toxic potential of the drug molecule [21].

Basically, saponin and cineole are the two active compounds contained in the formulas which can induce skin irritation [22-24]. It is necessary to take further steps in gathering scientific data regarding the toxic potential of experimental animals to ensure the safety of the oil. In the current study, an acute dermal irritation test was performed to determine the toxic effects of the topical single-dose test substance in albino rabbits. The test method used refers to The OECD Guideline for Testing of Chemical - No. Test: 404, Acute Dermal Irritation/Corrosion [25], as it is globally accepted in testing the safety of products and has been used in many researches [26-30].

## 2. MATERIALS AND METHODS

### 2.1 The Animals

Experimental animals used were three male albino rabbits, New Zealand strain, 10 months old in healthy condition and average weight of 2.23 Kg (W1 = 2.1 Kg, W2 = 2.2 Kg, and W3 = 2.4 Kg). They were acclimatized for five days in the experiment room at an individual cage with a temperature of 24-26°C, relative humidity of 60-70% and a lighting cycle of 12 hours of dark/light. They were given commercial pellet feed (Nova Rabbit Food - Perfect Companion Group Co., Ltd.) of 150 g/day and drinking water as necessary. The cages were equipped with labels

containing detailed information such as type of test, sex, and animal number.

## 2.2 Animals Development and Test Procedure

Preparation of experimental animals followed the OECD protocol for acute dermal irritation test. Approximately 24 hours before the test, fur should be removed by closely clipping the dorsal area of the trunk of the animals. Care should be taken to avoid abrading the skin, and only animals with healthy, intact skin should be used. The chemicals test (Minyak Rajas) were administered in a single dose of 0.5 mL on the prepared skin area (approximately 6 cm<sup>2</sup>) and covered with a sterile gauze patch, which is held in place with non-irritating tape. It contained active ingredients which have the potential to induce irritation. Therefore, it was necessary to perform an initial test for materials suspected to be irritants. The in vivo test is performed initially using one animal and applying the following approach. There are three test patches are applied sequentially to the animal. The first patch is removed after three minutes. If no serious skin reaction is observed, a second patch is applied at a different site and removed after one hour. If the observations at this stage indicate that exposure can humanely be allowed to extend to four hours, a third patch is applied and removed after four hours, and the response is graded. If a corrosive effect is observed after any of the three sequential exposures, the test is immediately terminated. If a corrosive effect is not observed after the last patch is removed, the animal is observed for 14 days, unless corrosion develops at an earlier time point. If a corrosive effect is not observed in the initial test, the irritant or negative response should be confirmed using up to two additional animals, each with one patch, for an exposure period of four hours. The extracted residue attached to the skins are subsequently removed with a neutral solvents, with the ability to maintain the integrity of the epidermis.

## 2.3 Observations and Evaluation

The duration of the observation period should be sufficient to evaluate fully the reversibility of the effects observed. However, testing must be stopped if the animal shows symptoms of toxicity or severe pain. All animals should be examined for visual assessment of erythema and edema parameters, and other toxicity responses at 1, 24, 48 and 72 hours after the patches are

opened. When there is damage that cannot be identified as irritation or corrosion at 72 hours, observation is needed until the 14<sup>th</sup> day. Therefore, in the evaluating irritation response, the reversibility of skin lesions should be considered. All local toxic, as well as systemic side effects, are recorded and responses such as alopecia, hyperkeratosis, hyperplasia, and scaling persist until the end of the observation period, thus the test chemicals are considered as irritants. The untreated skin areas of the test animal function as the control. The degree of irritation/corrosion was read and graded. The arbitrary scale scoring was: No erythema: 0, Very slight erythema: 1, Well defined erythema: 2, Moderate to severe erythema: 3, and severe erythema (beef redness): 4. As well as No oedema: 0, Very slight oedema: 1, Slight oedema: 2, Moderate edema (raised approximately 1 mm): 3, and Severe edema (raised more than 1 mm): 4. According to the Draize Test for classification of Primary Irritation Indexes (PII) was: Non-irritating: 0.5; Slightly irritating: 0.5-2.0; Moderately irritating: 2.0-5.0; and Highly irritating: 5.0-8.0 [25,31]. The PII of the test materials were calculated using the formula given below:

$$PII = \frac{\text{Sum of Erythema and edema}}{\text{No. of test sites} \times \text{No. of grading intervals}}$$

## 2.4 Data Analysis

The data of skin irritation, which showed the state of individual lesions for each experimental animal at 1, 24, 48, and 72 hours after the patches were opened, is presented descriptively. Furthermore, the Primary Irritation Index (PII) of skin irritation was classified according to the Amended Draize Test [26,32].

## 3. RESULTS AND DISCUSSION

### 3.1 Results

In the initial test, there were no lesions that showed dermal corrosion or irritation. Looks at all patches of test substances were no different compared to controls. After exposure for 4 hours, the patches were opened and skin irritation graded was performed at 1, 24, 48, and 72 hours. The results showed focal skin redness in one of the experimental animals and were categorized as a very slight erythema lesion. The color decreased at the 48<sup>th</sup> hour of observation and completely disappeared at the 72<sup>nd</sup> hour. Observation continued until the end of the 14<sup>th</sup> day, and no skin irritation or other signs of

toxicity were noticed. The results assessment is shown in the tables and figures below.

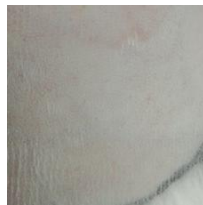### 3.2 Discussion

The skin protects the body against conditions outside the environment. These conditions are influenced by physical, chemical, and biological factors. Furthermore, it is an important site for

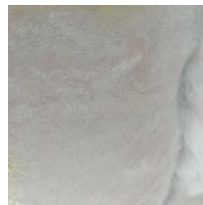vitamin D synthesis, and it acts as a thermoregulatory by maintaining a constant homeostatic value [33]. A positive skin irritation reaction is characterized by erythema (redness) and edema. Erythema caused by hyperemia in superficial capillaries of the skin or mucous membrane. Meanwhile, edema is a lesion caused by fluid accumulation in body tissues [28, 34].

**Table 1. Draizes kor irritation of minyak rajas in albino rabbits**


Time intervals	Animals	Minyak Rajas		
		Erythema	Oedema	Total score
1 hour	Rabbit 1	0	0	0
	Rabbit 2	0	0	0
	Rabbit 3	0	0	0
24 hours	Rabbit 1	0	0	0
	Rabbit 2	1	0	1
	Rabbit 3	0	0	0
48 hours	Rabbit 1	0	0	0
	Rabbit 2	1	0	1
	Rabbit 3	0	0	0
72 hours	Rabbit 1	0	0	0
	Rabbit 2	0	0	0
	Rabbit 3	0	0	0
Total irritation score				2
Primary Irritation Indexes				0.16
Result				Non-irritating



**Fig. 1. Control (1 hour)**



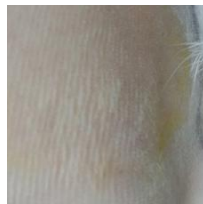**Fig. 3. Control (24 hours)**



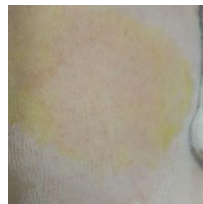**Fig. 5. Control (48 hours)**



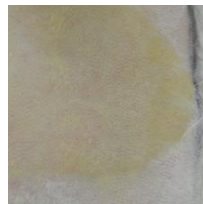**Fig. 7. Control (72 hours)**



**Fig. 2. Test (1 hour)**



**Fig. 4. Test (24 hours)**



**Fig. 6. Test (48 hours)**



**Fig. 8. Test (72 hours)**

*Figure. Response of acute dermal irritation test after 4-hour exposure to the test material. Fig. 1 showed control. Fig. 4 showed skin redness (erythema). Fig. 6 showed unclear skin redness indicated. Overall, Fig. 1 to Fig. 8 did not show any significant difference between the test material with the controls on different interval times of observations. There were no severe erythema and edema or other skin reactions and local toxic effects such as defeating or the effect of systemic changes at all of the examinations*

Visual observation of the experimental animals commenced before treatment was administered. In the initial test with exposure three patches each opened after 3 minutes, 1 hour and 4 hours, all showed no response to skin irritation including controls. Therefore, all assessments were given a zero score and the active ingredients in this natural medicine are classified as non-corrosive [31]. Observing the confirmation test after 24 hours of exposure, we found a skin irritation response in one of the three experimental animals. Very slight erythema lesions have been found in the area of the skin treated with test chemicals. The redness lasted about 48 hours, and at the 72nd-hour observations had disappeared. The results of the calculation of Primary Irritation Indexes were 0.16 for the test material and zero for control. According to the Draize test classification, Minyak Rajas is determined to be non-irritating and safe to use on the skin [26]. The reddish response to animal skin with a short duration is probably caused by the sensation of warmth from test material. It provides a warm sensation, causing capillary vasodilation in the skin, followed by increased blood flow and accumulation of plasma filtrate in interstitial tissue [34].

Factors that can influence the emergence of side effects or toxicity of herbal medicines are ingredients that have not been standardized, the dose that is not appropriate, the effect of constituent compound combination, and contaminated properties [35]. The *Zingiberis purpurei* herb contains active compound cineole which is toxic to the skin [18]. The active compound saponin in *Piperis betle* and *Curcuma aegerinosae* has been reported to be able to induce the irritation to the skin, mucous membranes, eyes and nose [16,22,30]. Nyigo et al. [29] reported that skin irritation occurs due to the active compound saponin in the *Synadenium glaucescens* extract formula. Natural veterinary medicine Minyak Rajas are derived from a number of herbal plants, specially formulated with effective microorganisms technology. This process is thought to reduce the potential irritation of cineole and saponin active compounds. Similar results were observed in the polyherbal mastilep gel test containing extracts of *Cedrus deodara*, *Curcuma longa*, *Glycyrrhiza glabra* and *Eucalyptus globulus* [28], and topical formulation of *Moringa oleifera* cream [26]. In line with research by Sohail et al. reported analgesic herbal cream formulas containing *Nigella sativa* seed oil not causing irritation with PII 0.04 [36].

The combination of various active ingredients in natural medicine is expected to produce synergistic pharmacological effects for the safe treatment of animals.

#### 4. CONCLUSION

An acute dermal irritation test of natural veterinary medicine was performed on albino rabbits. Based on the Draize Test, a Primary Irritation Indexes of 0.16 was obtained. Therefore, we concluded that the natural veterinary medicine of Minyak Rajas is non-irritating and safe for usage.

#### CONSENT

It is not applicable.

#### ETHICAL APPROVAL

All procedures for the use of experimental animals have followed the protocol and received approval from the Animal Ethics Committee, Faculty of Veterinary Medicine, Udayana University, with approval letter number: 14/UN14.2.9/PT.01.04/2020.

#### ACKNOWLEDGEMENTS

The authors are grateful to Songgolangit Persada Limited Company, Bali, Indonesia and the Faculty of Veterinary Medicine, Udayana University, Bali, which have provided the facilities, guidance and support needed in this research.

#### COMPETING INTERESTS

Authors have declared that no competing interests exist.

#### REFERENCES

1. Intahphuak S, Khonsung P, Panthong A. Anti-inflammatory, analgesic, and antipyretic activities of virgin coconut oil. *Pharm Biol.* 2010;48(2):151-157. DOI:<https://doi.org/10.3109/13880200903062614>
2. Praskash J, Pilerood SA. Chemical Composition and antioxidant properties of ginger root (*Zingiber officinale*). *Journal of Medicinal Plants Research.* 2010;4(24): 2674–2679. DOI:<https://doi.org/10.5897/JMPR09.464>

3. Mao QQ, Xu XY, Cao SY, Gan RY, Corke H, Beta T, Li HB. Bioactive compounds and bioactivities of ginger (*Zingiber officinale* Roscoe). Foods. 2019;8(6):185. DOI:https://doi.org/10.3390/foods8060185
4. Kaliyadasa E, Samarasinghe BA. Genus alpinia, a potential power house of bioactives: A review. Int J Pharm Sci Res. 2019;10(6):2644-2653. DOI:https://doi.org/10.13040/IJPSR.0975-8232
5. Amagai Y, Katsuta C, Nomura Y, et al. Amelioration of atopic-like skin conditions in NC/Tnd mice by topical application with distilled Alpinia intermedia Gagnep extracts. J Dermatol. 2017;44(11):1238-1247. DOI:https://doi.org/10.1111/1346-8138.13995
6. Ahlina FN, Nugraheni N, Salsabila IA, Haryanti S, Da'i M, Meiyanto E. Revealing the reversal effect of galangal (*Alpinia galanga* L.) extract against oxidative stress in metastatic breast cancer cells and normal fibroblast cells intended as a Co-Chemotherapeutic and anti-ageing agent. Asian Pac J Cancer Prev. 2020;21(1):107-117. DOI:https://doi.org/10.31557/APJCP.2020.21.1.107
7. Wibowo DP, Mariani R, Hasanah SU, Aulifa DL. Chemical constituents, antibacterial activity and mode of action of Elephant Ginger (*Zingiber officinale* var. officinale) and Emprit ginger rhizome (*Zingiber officinale* var. amarum) Essential Oils. Pharmacogn J. 2020;12(2):404-409. DOI:https://doi.org/10.5530/pj.2020.12.62
8. Vaughn AR, Branum A, Sivamani RK. Effects of turmeric (*Curcuma longa*) on skin health: A systematic review of the clinical evidence. Phytother Res. 2016;30(8):1243-1264. DOI:https://doi.org/10.1002/ptr.5640
9. Shan CY, Iskandar Y. Studi Kandungan Kimia dan Aktivitas Farmakologi Tanaman Kunyit (*Curcuma longa* L.). Farmaka. 2018;16(2):547-554. DOI:https://doi.org/10.24198/jf.v16i2.17610.g8793
10. Simoh S, Zainal A. Chemical profiling of *Curcuma aeruginosa* Roxb. Rhizome using different techniques of solvent extraction. Asian Pac J Trop Biomed. 2015;5(5):412-417. DOI:https://doi.org/10.1016/S2221-1691(15)30378-6
11. Ololade ZS, Abam EO, Anuluwa IA, Abiona OO. Secondary metabolites, pharmacognostic and therapeutic activities of the rhizome extract of *Curcuma longa* grown in South-West, Nigeria. J Phytopharmacol. 2020;9(1):30-37. DOI:https://doi.org/10.31254/phyto.2020.9.106
12. Ahmad RS, Hussain MB, Sultan MT, Arshad MS, Waheed M, Shariati MA et al. Biochemistry, safety, pharmacological activities, and clinical applications of turmeric: A mechanistic review. eCAM. 2020;7656919.p:14. DOI:https://doi.org/10.1155/2020/7656919
13. Liu RH, Fu LN, Chen LY, Ren G., Chen SS, Chen Z. Chemical constituents and pharmacology study of Imperata cylindrical rhizomes. J. Tradit Chin Med. 2010;22(4):80-83. DOI:https://doi.org/10.3969/j.issn.1674-6348.2013.03.011
14. Anggraeni N, Syamsunarno MRA, Widyastuti R, Puspitasari IM, Praptama S. Potential dual effect anti-inflammatory and anti-platelet of cogon grass ethanol extract on diabetic mice a preliminary study. IOP Conf. Series: J Physics. 2019;1246:012006. DOI:https://doi.org/10.1088/1742-6596/1246/1/012006
15. Salehi B, Zakaria ZA, Gyawali R, Ibrahim SA, Rajkovic J, Shinwari ZK, et al. Piper species: A comprehensive review on their phytochemistry, biological activities and applications. Molecules. 2019;24(7):1364. DOI:https://doi.org/10.3390/molecules24071364
16. Syahidah A, Saad CR, Hassan MD, Rukayadi Y, Norazian MH, Kamarudin MS. Phytochemical Analysis, Identification and Quantification of Antibacterial Active Compounds in Betel Leaves, Piper betleMethanolic Extract. Pak J Biol Sci. 2017;20(2):70-81. DOI:https://doi.org/10.3923/pjbs.2017.70.81
17. Aara A, Chappidi V, Ramadas MN. Antioxidant activity of eugenol in Piper betel leaf extract. J Family Med Prim Care. 2020;9(1):327-331. DOI:https://doi.org/10.4103/jfmpc.jfmpc\_809\_19

18. Kato E, Kubo M, Okamoto Y, et al. Safety assessment of bangle (*Zingiber purpureum* Rosc.) rhizome extract: acute and chronic studies in rats and clinical studies in human. *ACS Omega*. 2018;3(11):15879-15889.  
DOI:<https://doi.org/10.1021/acsomega.8b02485>
19. Anderson SE, Meade BJ. Potential health effects associated with dermal exposure to occupational chemicals. *Environ Health Insights*. 2014;8(Suppl1):51-62.  
DOI:<https://doi.org/10.4137/ehi.s15258>
20. Novak-Bilić G, Vučić M, Japundžić I, Meštrović-Štefekov J, Stanić-Duktaj S, Lugović-Mihić L. Irritant and Allergic Contact Dermatitis - Skin Lesion Characteristics. *ActaClin Croat*. 2018; 57(4):713-720.  
DOI:<https://doi.org/10.20471/acc.2018.57.04.13>
21. Parasuraman S. Toxicological screening. *J Pharmacol Pharmacother*. 2011;2(2): 74-79.  
DOI:<https://doi.org/10.4103/0976-500x.81895>
22. MSDS. Material Safety Data Sheet Saponin. Sigma-Aldrich Corporation, Product Safety - Americas Region; 2012. Available:<https://www.nwmissouri.edu/naturalsciences/sds/s/Saponin.pdf>
23. Mathieu RJ, Cheraghi N, Russo MA. Resident Rounds: Part III - Case Report: Betel Quid Induced Irritant Contact Dermatitis of the Hand. *J Drugs Dermatol*. 2016;15(6):789-790.  
Available:<https://jddonline.com/articles/dermatology/S1545961616P0789X>
24. Ortega YH, Mosquera DMG, Galapththi S, et al. Safety assessment of a traditionally used extract from leaves of *Bol do apurpurascens*. *J Ethnopharmacol*. 2016; 192:302-308.  
DOI:<https://doi.org/10.1016/j.jep.2016.07.009>
25. OECD. Test No. 404: Acute Dermal irritation/corrosion, organisation for economic cooperation and development guidelines for the testing of chemicals, Section 4, OECD Publishing, Paris; 2015.  
DOI:<https://doi.org/10.1787/9789264242678-en>
26. Ali A, Akhtar N, Mumtaz AM, Khan MS, Iqbal FM, Zaidi SS. In vivo skin irritation potential of a cream containing *Moringaoleifera* leaf extract. *Afr. J. Pharm. Pharmacol*. 2013;15(7):289-93.  
DOI:<https://doi.org/10.5897/AJPP12.890>
27. Banerjee S, Chattopadhyay P, Ghosh A, Pathak MP, Singh S, Veer V. Acute dermal irritation, sensitization, and acute toxicity studies of a transdermal patch for prophylaxis against (+/-) anatoxin-a poisoning. *Int J Toxicol*. 2013;32(4): 308-313.  
DOI:<https://doi.org/10.1177/1091581813489996>
28. Gatne MM, Tambe K, Ravikanth K. Acute dermal irritation study of polyherbal gel Mastilep in rabbits. *International Journal of Pharmaceutical Sciences and Research*. 2015;6(8):3473.  
DOI:[https://doi.org/10.13040/IJPSR.0975-8232.6\(8\).3473-77](https://doi.org/10.13040/IJPSR.0975-8232.6(8).3473-77)
29. Nyigo VA, Mdegela R, Mabiki F, Malebo HM. Assessment of Dermal Irritation and Acute Toxicity Potential of Extracts from *Synadenium glaucescens* on Healthy Rabbits, Wistar Albino Rats and Albino Mice. *European Journal of Medicinal Plants*. 2015;10(4):1-11.  
DOI:<https://doi.org/10.9734/EJMP/2015/20763>
30. Sari LM, Suyatna FD, Subita GP, Auerkar EI. Acute dermal toxicity study of areca catechu linn. extract in sprague-dawley rats. *Asian J Pharm Clin Res [Internet]*. 2016;9(9):209-11.  
DOI:<https://doi.org/10.22159/ajpcr.2016.v9s3.14462>
31. UN. Globally Harmonized System of Classification and Labelling of Chemicals (GHS). Fifth Revised Edition, United Nation, New York and Geneva; 2015. Available:<https://www.osha.gov/dsg/hazcom/ghsguideoct05.pdf>
32. Baldisserotto A, Buso P, Radice M, et al. *Moringaoleifera* Leaf Extracts as Multifunctional Ingredients for "Natural and Organic" Sunscreens and Photoprotective Preparations. *Molecules*. 2018;23(3):664.  
DOI:<https://doi.org/10.3390/molecules23030664>
33. Kolarsick PAJ, Kolarsick MA, Goodwin C. Anatomy and physiology of the skin. *Journal of the Dermatology Nurses' Association*. 2011;3(4):203-213.  
DOI:<https://doi.org/10.1097/JDN.0b013e3182274a98>

34. Berata IK, Winaya IBO, Adi AAAM, Adyanal BW. Veterinary Pathology. SwastaNulis. Denpasar; 2018.
35. Sasmito WA, Wijayanti AD, Fitriana I, Sari PW. The acute toxicity test of herbal medicine in mice based on Organization for Economic Co-operation and Development (OECD). Jurnal Sains Veteriner. 2015;33(2):234-239. DOI:<https://doi.org/10.22146/jsv.17924>
36. Sohail T, Yasmeen S, Imran H, Ferheen S, Atiq-u-Rehman, Khan RA. Standardization and skin irritation potential of herbal analgesic cream containing Nigella sativa seed oil. Bangladesh Journal of Medical Science. 2020;19:163-168. DOI:<https://doi.org/10.3329/bjms.v19i1.43891>

---

© 2020 Merdana et al.; This is an Open Access article distributed under the terms of the Creative Commons Attribution License (<http://creativecommons.org/licenses/by/4.0>), which permits unrestricted use, distribution, and reproduction in any medium, provided the original work is properly cited.

*Peer-review history:*  
*The peer review history for this paper can be accessed here:*  
<http://www.sdiarticle4.com/review-history/58243>