



## **The Morphology of Re-epithelized Skin Following Experimental Open Wound in Wistar Rat Treated with *Vitellaria paradoxa* Oil**

**Abiodun Oluwabusola Adedeji<sup>1</sup>, Patrick Kunle Orisadiran<sup>2\*</sup>,  
Abdulfatai Abdulrahman<sup>3</sup> and Thomas Kehinde Adenowo<sup>1</sup>**

<sup>1</sup>Department of Anatomy, Olabisi Onabano University, Ago Iwoye, Nigeria.

<sup>2</sup>Department of Biochemistry, Ladoke Akintola University of Technology, Ogbomoso, Nigeria.

<sup>3</sup>Department of Anatomy, Ladoke Akintola University of Technology, Ogbomoso, Nigeria.

### **Authors' contributions**

*This work was carried out in collaboration among all authors. Author AOA designed the study and wrote the protocol. Author PKO performed the statistical analysis and wrote the first draft of the manuscript. Author AA performed the statistical analysis. Author TKA managed the analyses of the study. All authors read and approved the final manuscript.*

### **Article Information**

DOI: 10.9734/APRJ/2019/v3i230062

#### Editor(s):

- (1) Dr. Vassya Bankova, Professor, Institute of Organic Chemistry with Centre of Phytochemistry, Bulgarian Academy of Sciences, Bulgaria.  
(2) Dr. Langa Tembo, Department of Plant Science, University of Zambia, Lusaka, Zambia.  
(3) Dr. Msafiri Yusuph Mkonda, Lecturer, Department of Geography and Environmental Studies, Solomon Mahlangu College of Science and Education, Sokoine University of Agriculture, Morogoro, Tanzania.

#### Reviewers:

- (1) Naveed Muhammad, Abbottabad University of Science and Technology, Pakistan.  
(2) Anthony O. Ochieng, Sumait University, Tanzania.

Complete Peer review History: <http://www.sdiarticle4.com/review-history/51653>

**Original Research Article**

**Received 14 August 2019**  
**Accepted 19 October 2019**  
**Published 07 December 2019**

### **ABSTRACT**

**Aims:** The present study assessed the morphology of re-epithelized skin following experimental open wound in rat model treated with *Vitellaria paradoxa* oil.

**Place and Duration of Study:** Anatomy Department, Olabisi Onabano University, Ago Iwoye and Biochemistry Department, Ladoke Akintola University of Technology, Ogbomoso, Nigeria between June, 2018 and March, 2019.

**Methodology:** Excision wounds were surgically created on three groups of ten rats each (II-IV). Group I was assigned as normal control (no surgery), Group II was treated with *Vitellaria paradoxa*

\*Corresponding author: E-mail: [pkorisadiran@pgschool.lautech.edu.ng](mailto:pkorisadiran@pgschool.lautech.edu.ng);

oil, Group III was treated with Dermazin and Group IV was treated with distilled water. Area (cm<sup>3</sup>) of the wound were measured on days 3, 6 and 9, the rate of wound healing, re-epithelization of the skin were assessed histologically while the thickness of the granular cells layer and the organization of the epidermal squamous cells were evaluated morphologically, the level of collagen was determined in the wounds treated with *Vitellaria paradoxa* oil and compared with the collagen level in wound treated with distilled water and dermazin.

**Results:** The wound areas significantly ( $P < 0.05$ ) reduced in *V. paradoxa* oil treated group indicating the comparative efficacy of *V. paradoxa* oil. Histological observations indicated gradual and complete re-epithelization of the skin in *Vitellaria paradoxa* oil treatments group. Increased in collagen deposition in *V. paradoxa* oil treated group is also observed ( $P < 0.05$ ).

**Conclusion:** The results of this morphology indicated that *V. paradoxa* oil is a good potential in re-epithelization of open wound with no clinical disadvantage such as body weight, rectal temperature, packed cell volume using rats as animal model.

**Keywords:** *Vitellaria paradoxa*; dermazin; morphology; collagen; re-epithelized.

## 1. INTRODUCTION

Wounds are physical injuries that result in an opening or break of the skin. Proper healing of wounds is fundamental for the renewal of obstructed anatomical continuity and disrupted functional status of the skin [1]. Healing is a complex and complicated process started in response to an injury that restores the function and integrity of damaged tissues [2]. Most conventional treatments for dermal wounds healing were aimed to reduce inflammation. However, the treatment can have a negative impact on wound healing such as atrophy, obesity, osteoporosis and glaucoma [3]. Alternative medicine of plant sources rich in various nutritional factors like proteins, carbohydrates and vitamins, have been used to reveal the promotion of wound healing, because restoring injured dermal tissues requires some amount of energy [4]. Furthermore, antioxidant activities found in plants have shown therapeutic potential of these resources for wound healing [5].

*Vitellaria paradoxa* commonly known as Shea butter tree (Sapotaceae); is the only species in the genus indigenous to Africa [6]. The *V. paradoxa* fruit consist of a thin tart nutritious pulp that surrounds a relatively large oil-rich seed from which the oil is extracted. *V. paradoxa* oil is an off-white fat extracted from the nut of African *Vitellaria paradoxa* [7], it is used by traditional healers as a treatment for rheumatism, inflammation of the nostrils, nasal congestion, leprosy, cough, and minor bone dislocation [8], soothing and enhance healing after circumcision, and for preventing stretch marks in African pregnant women [9]. There are no reports of

allergic reaction owing to consumption of the oil or its produce [10].

The major components of natural extracts of plants such as phenols, flavonoids and tannins are known to act as antioxidants [11]. This lead to the possibility of using plant resources for dermal wound healing, but the scientific evidence for the effects of potential bioactive compounds and their therapeutic effects is lacking [12]. The preliminary phytochemical screening of *V. paradoxa* oil shows the presence of tannins, alkaloids, saponins, steroids, flavonoids, anthraquinones and cardiac glycosides [13]. Therefore, the present study is to assess the morphology re-epithelized skin following experimental open wound in rat model treated with Shea butter and should be able to answer the following research questions.

## 2. MATERIALS AND METHODS

### 2.1 Sample and Sample Preparation

*Vitellaria paradoxa* oil were collected from Sagamu market in Ogun State, Nigeria then identified by a Botanist in the Department of Pure and Applied Biology, Ladoke Akintola University of Technology, Ogbomoso, Nigeria.

### 2.2 Animals

The protocol of the study was approved by the Local Ethical Committee for animal experimentation of the Faculty of Basic Medical Sciences of Olabisi Onabanjo University. 40 rats weighing 155-210 g were obtained from animal house of Physiology Department, Ladoke Akintola University of Technology, Ogbomoso,

Nigeria and kept in animal house in standard conditions ( $21^{\circ}\text{C} \pm 1^{\circ}\text{C}$ , humidity 45% and 12-h-light/12-h-dark cycle). They were provided food and water *ad libitum* during the whole period of the experiment.

### 2.3 Excision Wounds and Treatments

Thirty out of the rats were sedated with intraperitoneal injection of ketamine ( $80 \text{ mgkg}^{-1}$ ) and xylazine ( $10 \text{ mgkg}^{-1}$ ) and back were shaved; a lesion was made in the dorsal region with a 2 cm diameter. The animals were randomly distributed into 3 groups ( $n = 10/\text{group}$ ) after recovery from the surgical excision. The treatment was done once per day.

- Group I- Control (no surgery)
- Group II- *Vitalleria paradoxa* oil treated group
- Group III – Dermazin
- Group IV – Distilled water

### 2.4 Measurement of Wound Area

The progressive change in wound area was measured in mm at every 2 days interval. Progressive decrease in the wound size was monitored periodically.

### 2.5 Histological Examination

At day 13 the experiment was terminated and the wound area was removed from the surviving animals for histological examination. The tissue were processed for histological evaluation according to Tumen et al. [14], Briefly, samples were fixed in 10% buffered formalin, processed and blocked with paraffin. Then, samples were sectioned into 5  $\mu\text{m}$ -thick sections and stained with hematoxylin and eosin (H&E). The tissues were examined by light microscope (Olympus B x 51 attached d P70 Digital Camera System).

### 2.6 Collagen Special Stain (Masson's Trichrome Staining)

Masson trichrome's staining method was modified from Kiernan [15]. Briefly, granulation skin tissue slides were placed in staining jar and deparaffinized by submerging into three series of absolute xylene for 4 minutes each followed by 100%, 95%, 90%, 80% and 70% of ethanol for 4 minutes in each percentage. The slides then were submerged in warmed Bouin's solution at  $60^{\circ}\text{C}$  for 45 minutes. The slides were then washed in tap water until yellow colour in samples disappeared. To differentiate nuclei,

slides were immersed in modified Weigert's haematoxylin for 8 minutes, after that washed in running water for 2 minutes. In order to stain cytoplasm and erythrocytes, slides were submerged in anionic dyes, acid fuchsin (C.I. 42590, Merck, Germany) for 5 minutes; then again slides were washed with running tap water for 2 minutes. Next, slides were treated with phosphomolybdic acid solution for another 10 minutes as a mordant and immediately slides were submerged into methyl blue (C.I. 42780, Merck, Germany) solution for 5 minutes in order to stain fibroblast and collagen. After that, slides were washed in running water for 2 minutes and lastly treated with 1% acetic acid solution for 1 minute. Slides then were dehydrated into a series of alcohol of 70%, 80%, 95% and 100% for 1 minutes each percentage. Before observation, slides were dipped into absolute xylene for 1 minute and finally mounted with cover slip using DPX mounting.

### 2.7 Collagen Density Evaluation in Wound

Quantification of collagen deposition in normal wounded tissue stained with Masson's trichrome staining evaluated that collagen deposition and density was significantly ( $p < 0.05$ ) different for every group of post-wounding. Even though the gross observation showed complete epithelisation at day 13.

Ratio = (Average collagen intensity under wound/ Average collagen intensity of normal dermis) x100

### 2.8 Statistical Analysis

Statistical significance between means was analyzed by one-way ANOVA using SPSS 16.0 while  $P < 0.05$  was considered statistically as significant.

## 3. RESULTS

### 3.1 Effect of Different Treatment Parameters on Wound Area

The wound healing activity of *V. paradoxa* oil, dermzin and distill water was evaluated on rat in the excision wound models to confirm the wound healing ability. Fig. 1 showed the measured values of the closure progression of wound in different groups. After application of *V. paradoxa* oil onto wounds, the area of wound reduced 77.59% of their original size on day 4, 92.64% on

day 8 and 99.50% on day 13, and complete closure around day 14. In distill water treated animals, the area was reduced to 76.78% (day 4), 92.86% (day 8) and 99.93% (day 13). The wound closure in animals treated with reference drug, dermazin, were 62.05% (day 4), 30% and 92.63% (day 8), 99.78% (day).

### 3.2 Haematoxylin and Eosin (H&E) Staining

The stain in the control group (Plates 1 & 2) showed two principal layers Epidermis (E) and Dermis (D). The epidermis (E) was of stratified squamous epithelium with thin cornification (the stratum corneum). These projections of the sub-

epithelial layer into the basal part of the epidermis were the dermal papillae. The dermal papillae accommodated the respective epidermal pegs the bulk of the dermis is made primarily of dense irregular connective tissue. The epidermis of the healing wound showed gradual migration towards the thin epidermis and a process of re-epithelization of the skin during healing process (Plates 2 to 8). There were fewer intra dermal structures such as the hair follicles, the sebaceous gland, below the healing wound (Plates 7 & 8). The presence of the thin epidermis across the wound area was observed to substantiate the total closure of the wound area in treated rats at third weeks of healing process (Plates 7 & 8).

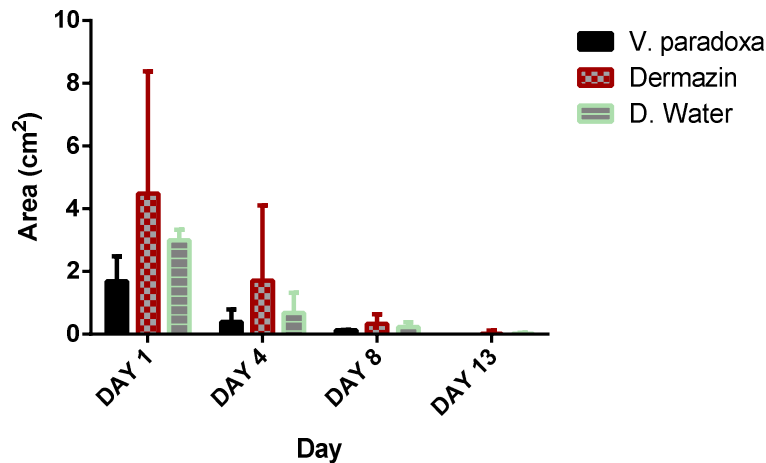


Fig. 1. Effect of different treatment parameters on wound area  
Results are presented as mean  $\pm$  SD with n = 10

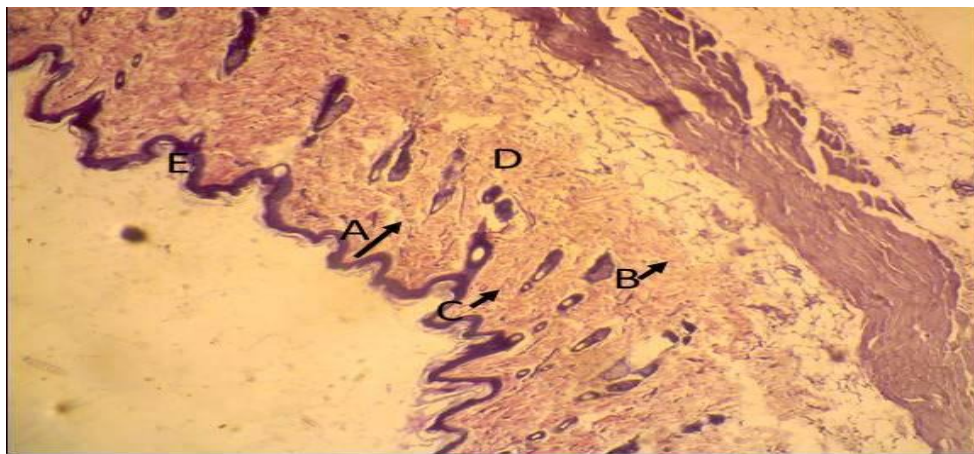


Plate 1. Normal control group: Showing normal cells of Hair shaft (A), Fibroblast (B) and Hair follicle (C) with intact Dermal (D) and Epidermal (E) layers. (H & E x100)

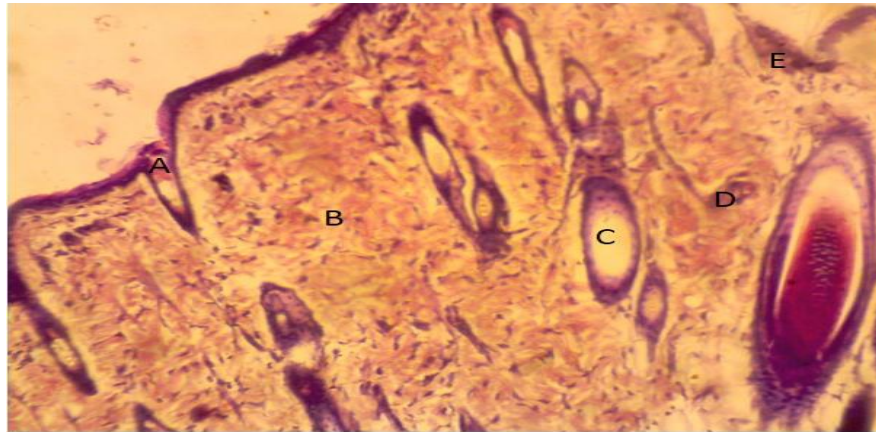


Plate 2. Normal control group: Showing normal cells of Hair shaft (A), Fibroblast (B) and Hair follicle (C) with intact Dermal (D) and Epidermal (E) layers. (H & E x400)

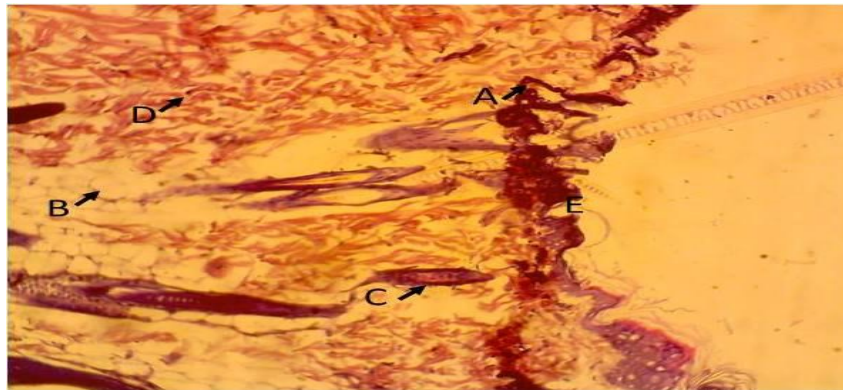


Plate 3. Histopathological characteristics of rat skin on 13<sup>th</sup> day by treatment with distilled water. Showing cells of Hair shaft (A), Fibroblast (B) and Hair follicle (C) with damage Dermal (D) and Epidermal (E) layers (H & E x100) (dermal layer appeared with scar)

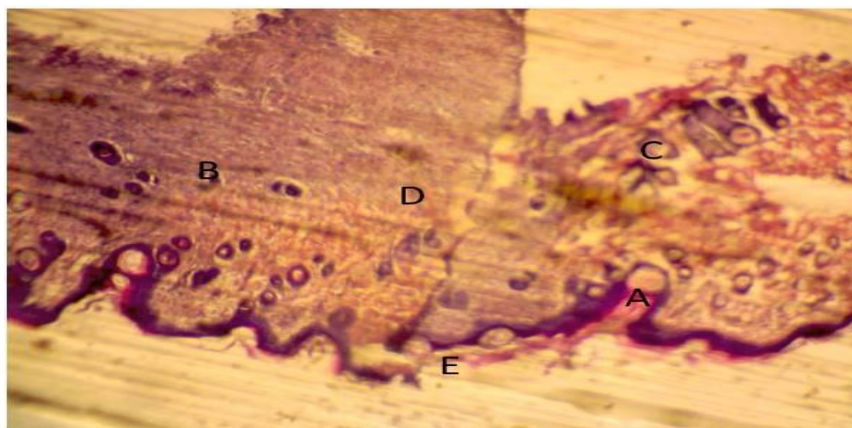
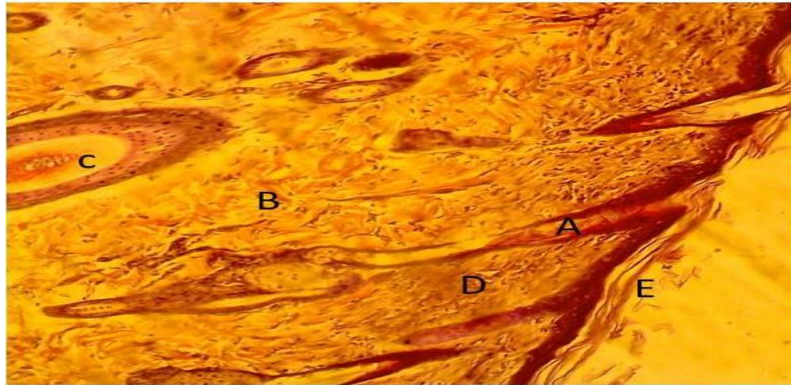
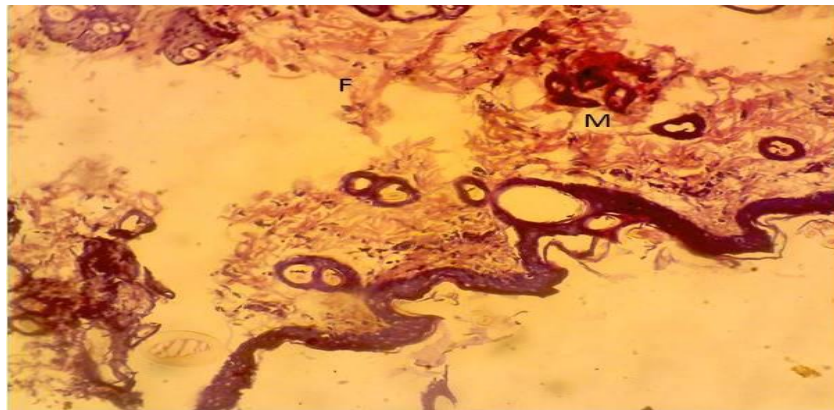


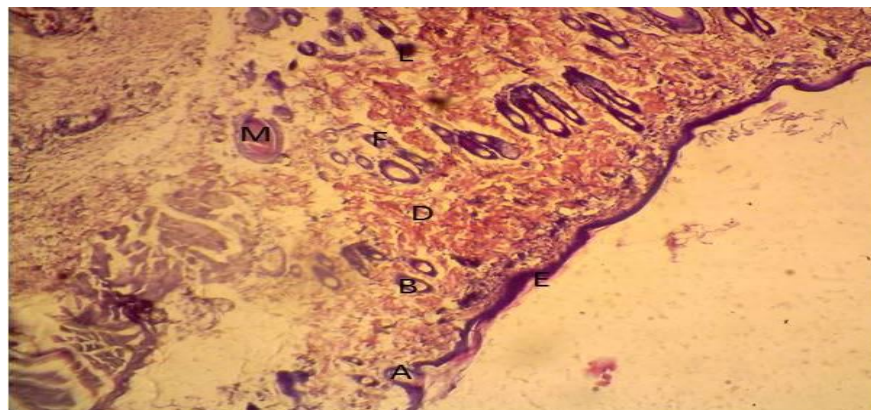
Plate 4. Histopathological characteristics of rat skin on 13<sup>th</sup> day by treatment with distilled water. Showing cells of Hair shaft (A), Fibroblast (B) and Hair follicle (C) with damage Dermal (D) and Epidermal (E) layers. (H & E x400). Sectioned shows epidermal ballooning, nuclear halo, preponderance of epithelioid cells



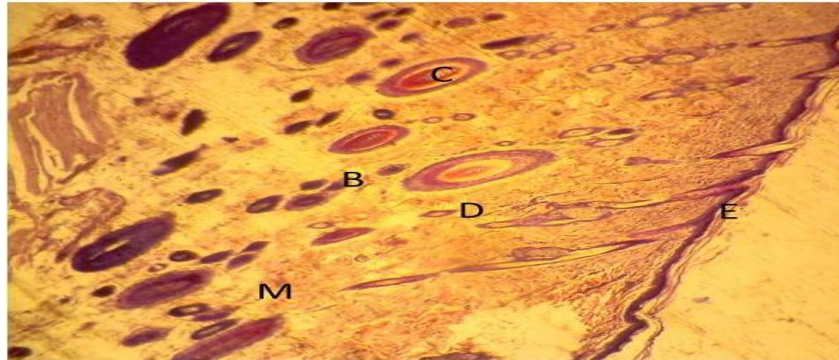
**Plate 5. Histopathological characteristics of rat skin on 13<sup>th</sup> day by treatment with Dermazin. Showing cells of Hair shaft (A), Fibroblast (B) and Hair follicle (C) with Dermal layer appeared with scar (D) and Epidermal (E) layers. (H & E x100)**



**Plate 6. Histopathological characteristics of rat skin on 13<sup>th</sup> day by treatment with Dermazin. Sectioned shows preponderance of fibrocytes (F) and macrophages (M) with or no lymphocyte. (H & E x400)**



**Plate 7. Histopathological characteristics of rat skin on 13<sup>th</sup> day by treatment with V. paradoxa oil. Sectioned shows intact dermal (D) and epidermal (E) layer, increase in the number of fibrocytes (F), Lymphocytes (L) and macrophages (M). (H & E x100)**



**Plate 8. Histopathological characteristics of rat skin on 13<sup>th</sup> day by treatment with *V. paradoxa* oil. Showing normal cells of Hair shaft (A), Fibroblast (B) and Hair follicle (C) with intact Dermal (D) and Epidermal (E) layers. (H & E x400)**

The sectioned shows increase in the number of fibrocytes and inflammatory infiltrates (Lymphocytes and macrophages (M)).

relative quantity of collagen fiber deposit, which reflects the process of synthesis and degradation and remodeling as well as the timing of the lesion [17].

### 3.3 Collagen Special Stain (Modified Masson's Trichrome Staining)

Histopathological examinations of the healed wounds are shown in plates 9 to 12. Masson-trichrome staining is a typically stain used to assess the advancement of collagen deposition during the formation of granulation tissue and matrix remodeling [16]. The blue colour staining intensity in the present study corresponds to the

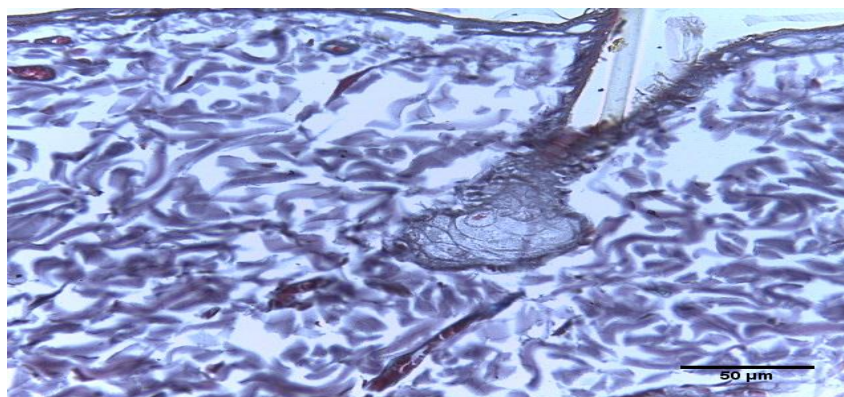
### 3.4 Collagen Density Evaluation

Quantification of collagen deposition in normal wounded tissue stained with Masson's trichrome staining showed that collagen deposition and density was significantly ( $p < 0.05$ ) different for every week of post-wounding as presented in Table 1. Even though the gross observation showed complete epithelisation at day 13.

**Table 1. Staining intensity**

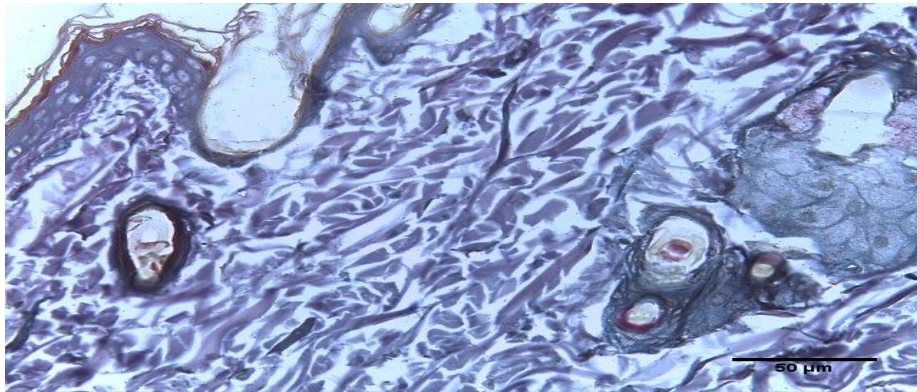
| Group     | Control       | Dermazin       | Distil water  | <i>V. paradoxa</i> |
|-----------|---------------|----------------|---------------|--------------------|
| Mean (SD) | 120.5 ± 2.439 | 139.4 ± 7.266* | 123.5 ± 4.277 | 141.1 ± 4.746*     |

All results are expressed as mean±SD. \*Significant at  $p < 0.05$

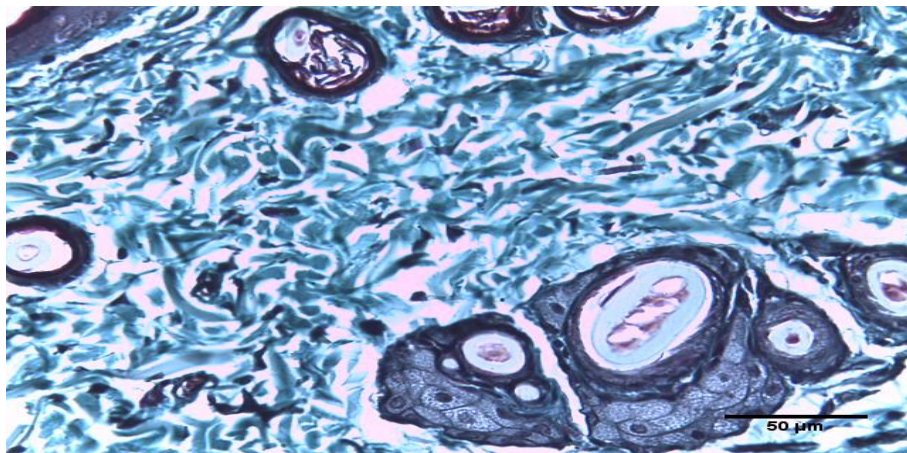


**Plate 9. Photomicrograph of the skin of Wistar rats of control showing thin areas of collagen deposition (Blue colour)**


Scale bar; 50µm. (Masson Trichome 400X)



**Plate 10.** Photomicrograph of the skin of Wistar rats treated with distilled water showing thin areas of collagen deposition (Blue colour)  
Scale bar; 50um. (Masson Trichome. 400X)



**Plate 11.** Photomicrograph of the skin of Wistar rats treated with *V. paradoxa* oil showing thick areas of collagen deposition (Blue colour)  
Scale bar; 50um. (Masson Trichome. 400X)



**Plate 12.** Photomicrograph of the skin of Wistar rats treated with Dermazin showing narrow areas of collagen deposition (Blue colour)  
Scale bar; 50um. (Masson Trichome. 400X)



#### 4. DISCUSSION

This research proved the effectiveness of *V. paradoxa* oil in rat skin wound healing after 13 days, besides the effect of oil on the anti-inflammatory activity, its boost in skin re-epithelialization, cell proliferation and extracellular cell matrix remodeling.

The synthesis of haemostatic clot at the wound site activates platelets and cells from the region to secrete cytokines which stimulate leukocyte infiltration into the region whereby initiating the inflammatory response [18]. Study by Senapati and co. [19] showed that both proinflammatory and anti-inflammatory factors are involved in mechanisms that comprise the three phases of wound healing. To prevent against chronic inflammation, delaying of healing mechanism, with possible loss of tissue function as a result of continuous secretion of cytokines and the debridement of the wound by leukocyte, however, the inflammatory response must occur rapidly for the proper healing of the lesions. Thus, the control of pro- and anti-inflammatory molecules is necessary for the physiological healing mechanism, with study of Kant et al. [20] demonstrating the use of plants to decrease inflammation of wounds.

Reepithelialization is another essential mechanism for skin wound healing and it begins some hours after the injury, but it has the most evident activity in the proliferative phase of healing, finishing during the remodeling of the extracellular matrix [21]. The keratinocytes present at the border of the wounds secrete growth factors that stimulate the proliferation and migration of these cells to the covering of the injured area [21].

Remodeling phase is the last stage of the process of skin wound healing by which the provisional extracellular matrix is restored, the injured area is completely reepithelialized, and a myofibroblast-mediated contractile response of the injury occurs. Myofibroblasts with multiple binding sites binds to collagen fibers and contract, reducing the wound area [22]. The results obtained showed that *V. paradoxa oil* affect myofibroblast differentiation through these pathways, with possibility of myofibroblast retraction being responsible for wound area reduction [23]. Together with hemostatic clot formation and inflammation, the cells of the region synthesize growth factor which stimulates cells migration and proliferation and the synthesis of provisional extracellular matrix

responsible for the local filling and maintenance of healing mechanisms until extracellular matrix is permanently restored [21].

The result showed enhancement of cutaneous healing, which appeared completed in 13th day with the application *V. paradoxa* oil. The histological findings showed that the original tissue regeneration is much greater in skin wounds treated with the oil than in wounds distilled water treated rat. The wound contraction is mediated by specialized myofibroblasts found in the granulated tissue [24]. Therefore, the increase in wound contraction in *V. paradoxa* oil treated group might be a result of the enhanced activity of fibroblasts [24].

Response to injury involves the migration and proliferation of cells such as endothelial, fibroblasts and epithelial cells and deposition of connective tissue and contraction of the wound. Collagen plays an important role in homeostasis and in epithelialization at the later phase of healing as well as confers strength and integrity to the tissue matrix [25]. The present finding revealed that treatment with *V. paradoxa* oil caused an increased in the deposition of the bands of collagen, a phenomenon that appears to contribute with the increase in wound contraction [25].

Skin wound healing starts immediately after injury and consists of three phases: inflammation, proliferation, and maturation. The first response is inflammation, acting as a defense mechanism of the tissue, able to provide a resistance to the microbial contaminations [26]. But, a long duration in the inflammatory phase causes a delay in healing process. Anti-inflammatory activity is necessary to shorten the healing period [27]. Therefore, the wound healing activity of *V. paradoxa* may be related to its remarkable anti-inflammatory effect as presented in studies of Silva et al. [28] and Thomazzi et al. [29].

Collagen fiber plays a dominant role in preserving the anatomic integrity of wound healing. When tissues are disrupted following injury, collagen is needed to repair the defect in order to restore anatomic structure and function. Enoch and Leaper [30] reported that the three alpha chains of collagen intertwine into a triple helix which is very important in all stages of the wound healing process as it provides strength and integrity to all tissues. Kondo [26] confirmed that secretion of collagen subtype increases during the proliferative phase of the wound

healing mechanism within the injury site to replace necrotic tissue. Meanwhile in the remodeling phase of the wound healing process, the collagen is cross-linked into a more organized structure to produce greater wound tensile strength [22].

Greater tissue regeneration was observed in the *V. paradoxa* treated group and Dermazin treated group as demonstrated by the complete epithelization, significantly higher collagen deposition and granulation tissues compared to the healed wounds dressed with Dermazin and distilled water. The increased hydroxyproline content of the granulation tissue of the treatment groups is an indication of increased collagen turnover. Collagen provides strength and support to the extracellular tissue as the major component of granulation tissue which is the foremost constituent. It is composed of the amino acid, hydroxyproline, which is used as a biochemical marker for tissue collagen [31].

The present investigation showed that the greater collagen deposition in *V. paradoxa* treated wounds. This observation indicates that the collagen deposition in treated wounds must have undergone a greater degree of cross-linking resulting in an ultimate increase in wound strength, which was further confirmed by the tensile strength of the wounds.

## 5. CONCLUSION

The results of the study indicated that *V. paradoxa* oil is a good potential in re-epithelization of open wound with no clinical disadvantage such as body weight, rectal temperature, packed cell volume using rats as animal model.

## ETHICAL APPROVAL

The protocol of the study was approved by the Local Ethical Committee for animal experimentation of the Faculty of Basic Medical Sciences of Olabisi Onabanjo University, Nigeria.

## ACKNOWLEDGEMENT

We appreciate Sharpor Computers for their support throughout the period of this research.

## COMPETING INTERESTS

Authors have declared that no competing interests exist.

## REFERENCES

1. Begum D, Nath SC. Ethnobotanical review of medicinal plants used for skin diseases and related problems in Northeastern India, Journal of Herbs, Spices and Medicinal Plants. 2000;7:55–93.
2. Govindarajan RA, Pushpangadan P, Kumara B, Vijayakumar M. Ethnopharmacological approaches to wound healing Exploring medicinal plants of India. J Cell Sci. 2007;111:1929–1934.
3. McDonough AK, Curtis JR, Saag KG. The epidemiology of glucocorticoid-associated adverse events. Curr. Opin. Rheumatol. 2008;20:131–137.
4. Wild T, Rahbarnia A, Kellner M, Sobotka L, Eberlein T. Basics in nutrition and wound healing. Nutrition. 2010;26:862–866
5. Lodhi S, Singhai AK. Wound healing effect of flavonoid rich fraction and luteolin isolated from *Martynia annua* Linn. On streptozotocin induced diabetic rats. Asian Pac. J. Trop. Med. 2013;6:253–259.
6. Lovett P, Hag N. Evidence for a tropic selection of the Shea nut tree (*Vitellaria paradoxa*). Agro-forestry Systems. 2000; 48:293-304
7. Alfred T. "Fats and Fatty Oils". Ullmann's Encyclopedia of Industrial Chemistry. Weinheim: Wiley-VCH. 2002.
8. Olaniyan AM, Oje K. Quality characteristics of shea butter recovered from shea kernel through dry extraction process. J. Food Sci Technol. 2007;44:404-407.
9. Goreja WG. Shea Butter: The Nourishing Properties of Africa's Best-Kept Natural Beauty. Amazing Herbs Press. New York, NY; 2004.
10. Kanwaljit KC, Ramon B, Rosalia A, Galina G, Anna NW. Shea butter contains no IgE-binding soluble proteins. Letter to the editor. J Allergy Clin Immunol. 2010;127 (3):680–682.
11. Tapiero H, Tew GN, Mathe G. Polyphenols: Do they play a role in the prevention of human pathologies?. Biomed. Pharmacother. 2002;56:200-207
12. Che CT, Wang ZJ, Chow MS, Lam CW. Herb-herb combination for therapeutic enhancement and advancement: Theory, practice and future perspectives. Molecules. 2013;18:5125–5141.
13. Akoma O, Nma N, Musa S, Salihu A. Nutritional and Phytochemical Composition of *Vitellaria paradoxa* (Shea Fruit Pulp). Int J Biochem Res Rev. 2018;22(1):1–7.

14. Tumen I, Suntar I, Keles H, Akkol EK. A therapeutic approach for wound healing by using essential oils of cupressus and juniperus species growing in Turkey. *Evid Based Complement Alternat Med.* 2012;7.
15. Kiernan JA. *Histological and histochemical method (theory and practice)*, fourth edition. United Kingdom. Scion Publishing; 2008.
16. Braiman-Wiksman L, Solomonik I, Spira R, Tennenbaum T. Novel insights into wound healing sequence of events. *Toxicol Pathol.* 2007;35:767-779.
17. Aramwit P, Sangcakul A. The effects of sericin cream on wound healing in rats. *Biosci, Biotechnol Biochem.* 2007;71: 2473-2477.
18. Reinke JM, Sorg H. Wound repair and regeneration. *European Surgical Research.* 2012;49(1):35-43
19. Senapati AK, Giri RK, Panda DS, Satyanarayan S. Wound healing potential of *Pterospermum acerifolium* wild. with induction of tumor necrosis factor- $\alpha$ . *Journal of Basic and Clinical Pharmacy.* 2011;2:203-206.
20. Kant V, Gopal A, Pathak NN, Kumar, Tandan SK, Kumar D. Antioxidant and anti-inflammatory potential of curcumin accelerated the cutaneous wound healing in streptozotocin-induced diabetic rats," *International Immunopharmacology.* 2014; 20(2):322-330
21. Singer AJ, Clark RA. Cutaneous wound healing. *The New England Journal of Medicine.* 1999;341:738-746.
22. Gilliver SC, Emmerson E, Bernhagen J, Hardman M J. MIF: A key player in cutaneous biology and wound healing. *Experimental Dermatology.* 2011;20(1):1-6.
23. Zhao R, Li QW, Li J, Zhang T. Protective effect of *Lycium barbarum* polysaccharide 4 on kidneys in streptozotocin- induced diabetic rats. *Canadian Journal of Physiology and Pharmacology.* 2009;87 (9):711-719
24. Moulin V, Auger FA, Garel D, Germain L. Role of wound healing myofibroblasts on re-epithelization of human skin. *Burns.* 2000;26: 3.
25. Clark RAF. Wound repair: Overview and general considerations. In: CLARK RA AND HENSON PM. *The molecular and cellular biology of wound repair*, 2<sup>nd</sup> Ed, New York: Plenum. 1996;3-50.
26. Kondo T. Timing of skin wounds. *Leg Med.* 2007;9:109-114.
27. Shimizu N., Watanabe T, Arakawa T, Fujiwara Y, Higuchi K, Kuroki T. Pentoxifylline accelerates gastric ulcer healing in rats: Roles of tumor necrosis factor alpha and neutrophils during the early phase of ulcer healing. *Digestion* 2000;61:157-164.
28. Silvam JP, Rodarte RS, Cal heiros AS, Souza CZ, Amen doeira FC, Martins MA, Silva PM, Frutuoso VS, Barreto E. Antinociceptive activity of aqueous extract of *Bowdichia virgilioides* in mice. *J Med Food.* 2010;13: 348-351.
29. Thomazzi SM, Silva CB, Silveira DC, Vasconcellos CL, Lira AF, Cambui EV, Estevam CS, Antonioli, AR. Antinociceptive and anti-inflammatory activities of *Bowdichia virgilioides* (sucupira). *J Ethnopharmacol.* 2010;127: 451-456.
30. Enoch S, Leaper D. Basic science of wound healing. *Surgery.* 2008;26:31-7.
31. Pattanayak SP, Sunita P. Wound healing, anti-microbial and antioxidant potential of *Dendrophthoe falcata* (L.f) Ettingsh. *J Ethnopharmacol.* 2008;120:241-7.

© 2019 Adedeji et al.; This is an Open Access article distributed under the terms of the Creative Commons Attribution License (<http://creativecommons.org/licenses/by/4.0>), which permits unrestricted use, distribution, and reproduction in any medium, provided the original work is properly cited.

*Peer-review history:*  
The peer review history for this paper can be accessed here:  
<http://www.sdiarticle4.com/review-history/51653>